

Temporomandibular joint sequelae after whiplash trauma

Long-term, prospective, controlled study

HANNA SALÉ



Department of Odontology
Faculty of Medicine, Umeå University
SE-901 87 Umeå, Sweden
Umeå 2011

Copyright© by Hanna Salé 2011
ISBN: 978-91-7459-265-8
ISSN: 0345-7532
Front cover: Fredrik Bryndahl
Printed by: Print & Media, Umeå, Sweden 2011

To Sebastian, Märtha, and Leah

Contents

PREFACE	5
DEFINITIONS AND ABBREVIATIONS	6
ABSTRACT	7
INTRODUCTION	9
AIMS	15
MATERIALS AND METHODS	16
RESULTS	23
DISCUSSION	33
CONCLUSIONS	42
ACKNOWLEDGEMENTS	43
REFERENCES	45
APPENDICES	53
PAPER I-IV	

Preface

This thesis is based on the following papers, which are referred to in the text by their Roman numerals:

- I Salé H, Hedman L, Isberg A. Accuracy of patients' recall of temporomandibular joint pain and dysfunction after experiencing whiplash trauma: a prospective study. J Am Dent Assoc 2010;141:879-886.
- II Salé H, Isberg A. Delayed temporomandibular joint pain and dysfunction induced by whiplash trauma: A controlled prospective study. J Am Dent Assoc 2007;138:1084-1091.
- III Salé H, Bryndahl F, Isberg A. 15-year natural course of temporomandibular joints in asymptomatic and symptomatic non-patient volunteers. A prospective clinical and MR imaging study. Submitted manuscript.
- IV Salé H, Bryndahl F, Isberg A. 15-year follow-up of temporomandibular joint symptoms and MR imaging findings in whiplash patients. A prospective, controlled study. Manuscript.

Papers I and II are reprinted by permission of Journal of American Dental Association (Copyright © 2011 American Dental Association. All rights reserved).

Definitions and abbreviations

TMJ	Temporomandibular joint. The articulation between the mandible and the temporal bone of the facial skeleton.
MR imaging	Magnetic resonance imaging, a radiographic technique for visualizing structures without the use of ionizing radiation.
Whiplash trauma	An acceleration-deceleration mechanism of energy transfer to the neck, which may result from motor-vehicle collisions etc.
WAD	Whiplash-Associated Disorders. Clinical manifestations of injuries after whiplash trauma e.g. neck pain and TMJ pain.
Prevalence	A measure of how common a condition is by calculating the proportion of individuals in a population having a condition at a given time.
Incidence	A measure of the risk of developing a new condition by calculating the proportion of new individuals in a population who contract a condition during a specified period of time.
Progression	A measure of the risk of increasing severity of a condition by calculating the proportion of individuals in a population who have aggravation of a condition during a specified period of time.

Anatomical terminology is in accordance with internationally accepted terminology developed by FICAT (Federative International Committee on Anatomical Terminology) (1998).

Abstract

Whiplash-related injuries and manifestations, typically neck pain, following car collisions are known to potentially disable individuals with a high and increasing cost to society. There is limited knowledge regarding the temporomandibular joint (TMJ) sequelae following whiplash trauma. Previous studies are typically based on retrospective data and few follow-ups are prospective and controlled in design. Furthermore, previous follow-ups have not included magnetic resonance (MR) imaging, which is a prerequisite for verification of TMJ status.

The aims of this prospective long-term study were (i) to determine frequency of inaccurate recall of TMJ symptoms in patients with a history of whiplash trauma, and (ii) to evaluate incidence, prevalence and progression of TMJ pathology, verified with MR imaging, and TMJ symptoms in patients after whiplash trauma, compared with the natural course in matched volunteers.

We studied 60 consecutive patients who had neck symptoms following a rear-end car collision and were seen at a hospital emergency department. Bilateral TMJ MR imaging and clinical examination were performed at inception and at follow-up on average 15 years later. A self-administered questionnaire regarding TMJ symptoms (pain, dysfunction, or both) and a subsequent interview were performed at inception, at the one-year, and 15-year follow-up. Fifty-seven patients (95%) participated in all three examinations (85% for MR imaging examinations). Concurrently, 53 volunteers matched by age and sex followed the same protocol. Fifty volunteers (94%) participated in all three examinations (89% for MR imaging examinations). Ethics approval of the study protocol and informed consent from all participants was obtained.

The calculated agreement between each patient's inception and retrospective reports on TMJ symptoms yielded a kappa value of 0.41 (95% CI 0.18-0.64). Sixteen patients (40%) had inaccurate recall one year after whiplash trauma. There was no statistically significant difference in TMJ symptoms reported by the patients to be present before whiplash trauma compared with matched volunteers at inception. Prevalence of TMJ symptoms increased significantly with whiplash trauma and the increase remained stable throughout the 15-year study period, which contrasted to the natural course in volunteers. After one year the difference in prevalence between patients and volunteers was 54% versus 21% ($p=0.0003$) and after 15 years 49% versus 18% ($p=0.0017$). There was no statistically significant difference between patients and volunteers in prevalence of TMJ disc displacement either at inception (63%

versus 53%) or at 15-year follow-up (63% versus 55%). TMJ disc displacement was significantly more prevalent in symptomatic volunteers compared with asymptomatic volunteers (89% versus 31%, $p=0.0002$). Incidence or progression of MR imaging verified TMJ pathology did not differ between patients and volunteers.

This prospective 15-year follow-up concludes

- that future studies on TMJ sequelae following whiplash trauma should be prospective in study design with examinations conducted in close proximity to whiplash trauma. This allows for reliable baseline status and potential bias of inaccurate recall of symptoms is minimized.
- that future controlled studies on TMJ pathology in patients should include control groups of not only asymptomatic but also symptomatic volunteers in order to avoid potentially biased conclusions.
- that one of three patients exposed to whiplash trauma can be expected to develop TMJ symptoms beyond that which corresponds to the natural course in volunteers. This finding and previously reported impairment of jaw function in patients with symptoms after whiplash trauma points to the need for including TMJs and related muscles in routine medical examinations of patients with symptoms following whiplash trauma.
- that adult individuals presenting with no or mild TMJ symptoms seldom show development or aggravation of TMJ pathology and there is no or little indication for TMJ treatment of these adult individuals. This is in contrast to the higher progression of TMJ pathology previously reported for adult patients with TMJ symptoms, which requires treatment.

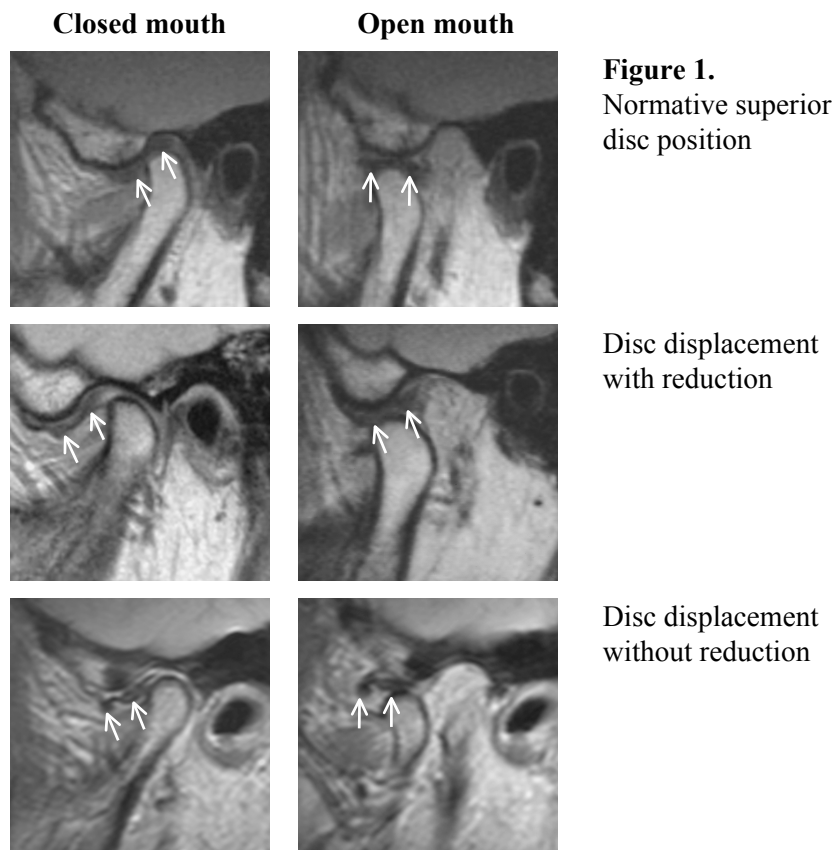
Introduction

The temporomandibular joint

Jaw movements require a unified action of the two temporomandibular joints (TMJ). The bony components of the TMJ are the condylar process of the mandible, and the mandibular fossa and articular tubercle of the temporal bone. In normal functioning TMJs, the articular disc fills the space between the two bony components during all jaw movements.

TMJ disc displacement

By far the most common pathology in the TMJ is disc displacement. TMJ disc displacement can occur in any direction, with anterior and anterolateral displacements being most common (Tasaki et al. 1996). Disc displacement is reducing if the disc resumes a normative superior position relative to the condyle on mouth opening. If the disc remains displaced during mouth opening, the displacement is non-reducing (Fig. 1).



Disc displacement can be diagnosed clinically when the displacement is associated with joint clicking, but displacement can occur without any joint sounds. Magnetic resonance (MR) imaging is currently the best radiographic method for visualizing TMJ soft tissues and depicts disc displacement with a high accuracy (Westesson et al. 1987a, Westesson 1987b, Katzberg et al. 1988, Schwaighofer et al. 1990, Tasaki, Westesson 1993). MR imaging is a radiographic technique for visualizing structures without the use of ionizing radiation.

The prevalence of disc displacement is significantly higher in patients with TMJ symptoms (77-82%) than in asymptomatic volunteers (30-35%) (Katzberg et al. 1996, Tasaki et al. 1996, Larheim et al. 2001a). The high prevalence of disc displacement in asymptomatic volunteers led to the suggestion that disc displacement was a congenital abnormality (de Bont et al. 1997). This hypothesis was disputed by an MR imaging study of 60 TMJs in 30 infants and young children aged 2 months to 5 years revealing no case of disc displacement, implying that disc displacement is an acquired condition (Paesani et al. 1999).

Individuals with TMJ symptoms who have not felt a need for treatment form a group of non-patients to date not considered or included in MR imaging studies of TMJ pathology. Together with the asymptomatic individuals, they comprise the general non-patient population, but their TMJ characteristics such as disc displacements are yet not known.

Natural course of TMJ disc displacement

Knowledge regarding the natural course of TMJ disc displacement is limited and few studies have verified disc position radiographically both at inception and follow-up. The increase in prevalence of disc displacement with age found in children and adolescents with asymptomatic TMJs points to a high incidence early in life (Paesani et al. 1999, Hans et al. 1992, Kecik et al. 2004, Masi et al. 2009, Tominaga et al. 2007, Ribeiro et al. 1997) (Fig. 9 page 40), which was confirmed by an MR imaging study on the incidence of disc displacement in asymptomatic adolescents over a study period of 2-3 years (Tominaga et al. 2007). The natural course of disc displacement in adult asymptomatic volunteers as well as adult symptomatic volunteers (non-patients) remains unknown because of no available studies with MR imaging both at inception and follow-up in these groups.

One of five patients with TMJ pain and radiographically verified reducing disc displacement at inception showed clinical signs of progression to displacement without reduction within 6 months. Progression was more likely in patients with pronounced joint pain, disturbed joint function and temporary locking (Westesson, Lundh 1989). One of eleven patients with no or

mild TMJ pain and clinically diagnosed reducing disc displacement demonstrated clinical signs of progression to displacement without reduction after three years (Lundh et al. 1987). When adolescent and adult patients with non-reducing disc displacement (Sato et al. 1999) and asymptomatic adolescent volunteers with reducing disc displacement (Tominaga et al. 2007) were re-examined radiographically after approximately two years, all TMJs maintained their disc status, pointing to a chronic nature of the condition.

Whiplash trauma

Whiplash is defined as an acceleration-deceleration mechanism of energy transfer to the neck. It may result from motor vehicle collisions, in particular rear-end collisions, but can also be the result of other types of trauma. The impact may result in bony or soft-tissue injuries, which in turn may lead to a variety of clinical manifestations. The classification system that has been used to date was introduced by the Quebec Task Force in 1995. Signs and symptoms are classified into whiplash-associated disorders (WAD) grade 0 through 4 (Table 1). Signs and symptoms that can occur in all grades include deafness, dizziness, tinnitus, headache, memory loss and TMJ pain (Spitzer et al. 1995).

The incidence of whiplash injuries in Sweden is 3.2/1000, excluding fractures and dislocations of the cervical spine (Sterner et al. 2003). The majority of injured individuals recover, but in one fourth to one half of these patients the symptoms become chronic i.e. persist at least six months after the whiplash trauma (Holm et al. 1999, Sterner et al. 2003, Carroll et al. 2009).

Table 1. The Quebec Task Force WAD classification	
Grade	Clinical presentation
0	No neck complaint and no physical signs
1	Neck complaint of pain, stiffness, or tenderness No physical signs
2	Neck complaint <i>and</i> musculoskeletal signs ¹
3	Neck complaint <i>and</i> neurological signs ²
4	Neck complaint <i>and</i> fracture or dislocation of cervical spine
¹ Include decreased range of motion and point tenderness	
² Include decreased or absent tendon reflexes, weakness, sensory deficits	

Whiplash trauma and the TMJ

Whether TMJ pain and dysfunction can be induced by whiplash trauma has been under extensive debate over the past three decades. Different explanations have been proposed regarding plausible trauma mechanism. One hypothesis was that the cervical extension phase induces rapid mouth opening resulting in stretching and tear of the TMJ soft tissues, and that the subsequent cervical flexion results in rapid mouth closure and thereby crushing of the structures (Weinberg, LaPointe 1987). Another hypothesis was that the mouth remains closed during both cervical extension and flexion movements and compression forces act on the TMJ structures (Howard et al. 1991).

An association between whiplash trauma and TMJ symptoms has been reported by some authors, while others failed to observe any such association. Many of these studies, however, were limited by retrospective study design, unclear trauma event and selection bias. One prospective but uncontrolled study examined patients directly after whiplash trauma and reported a low incidence of TMJ symptoms during the following year (Heise et al. 1992). One controlled study found a low prevalence of TMJ symptoms both in the trauma group and the control group two years after the collision. However, immediate post-traumatic neck symptoms were reported only by 28% of subjects, hence, there might not have been any significant whiplash trauma resulting from the collision in the majority of subjects (WAD grade 0) (Ferrari et al. 1999). In the two studies, the reported prevalence of TMJ symptoms such as clicking was considerably lower than in the general population (Hansson, Nilner 1975, Solberg et al. 1979, Dworkin et al. 1990, Pöllman 1993). The generalizability of the results may therefore be questioned.

When patients with immediate neck symptoms induced by whiplash trauma were examined directly after a car collision in the present comprehensive prospective project, one of seven patients reported immediate onset of TMJ symptoms (Bergman et al. 1998). A population-based study confirmed this result in the report of an immediate onset of reduced and/or painful jaw movement in one of seven subjects (Carroll et al. 2007). Two controlled studies showed a significantly higher prevalence of TMJ pain and a tendency for higher prevalence of TMJ pain, respectively, in patients two to three weeks after whiplash trauma compared with control subjects (Kronn 1993, Kasch et al. 2002). These results point to TMJ symptoms being induced by whiplash trauma.

Information regarding the long-term course of radiographically verified TMJ pathology is lacking, and the available information on long-term course of symptoms after whiplash trauma is limited. This knowledge is essential for

prognosis and treatment decisions, which emphasizes the need for long-term follow-up studies after whiplash trauma.

Whiplash trauma and TMJ disc displacement

An association between whiplash trauma and TMJ disc displacement has previously been claimed. This claim was based on a high prevalence of radiographically verified TMJ disc displacement observed in patients with TMJ symptoms and a history of whiplash trauma (Weinberg, LaPointe 1987, Pressman et al. 1992, Garcia, Arrington 1996). These studies did not include a control group. In fact, the reported prevalence of disc displacement in these studies was equally high in patients with TMJ symptoms but no specific history of whiplash trauma (Tasaki et al. 1996, Katzberg et al. 1996, Larheim et al. 2001a). Moreover, the studies relied on the patients' retrospective reports of a post-traumatic onset of TMJ symptoms given months after collision being accurate. Contradictory evidence emerged from the present comprehensive project when consecutive patients were examined directly after whiplash trauma revealing no MR imaging findings indicating acute injury such as bleeding or edema in the soft tissues. Furthermore, the prevalence of disc displacement did not differ between patients and control subjects (Bergman et al. 1998). Whether whiplash trauma has an effect on the long-term incidence and progression of TMJ disc displacement has not been investigated.

Whiplash trauma and functional jaw/neck disturbance

Deranged jaw function has been revealed in patients with chronic neck symptoms after whiplash trauma. These patients had a decreased amplitude and impaired coordination of integrated jaw and head-neck movements compared with healthy subjects, as well as impaired endurance and report of pain and discomfort during chewing (Häggman-Henrikson et al. 2002, Häggman-Henrikson et al. 2004, Grönqvist et al. 2009). In line with this, patients with chronic neck symptoms after whiplash trauma had a higher prevalence of pain and other symptoms in the TMJs and related muscles compared with control subjects (Klobas et al. 2004, Visscher et al. 2005).

Memory of symptoms

When investigating sequelae after whiplash trauma, the temporal order of the two events is a crucial factor, i.e. that the whiplash trauma truly preceded the incidence or progression of pathology or symptoms. Examining patients after collision is the only option because of ethical considerations, but the proximity of the collision and examination can be a difficult task in a research setting. This may be a reason why patients have been examined several weeks or months after whiplash trauma in many studies. However,

retrospective reports of symptoms require that the patients recall symptoms accurately over time.

Patients recall symptoms in various body regions accurately from one day up to as long as two weeks (Hunter et al. 1979, Singer et al. 2001, Bryant et al. 2006). But when the recollection period is three weeks or longer memory of chronic symptoms can be inaccurate (Raphael, Marbach 1997, Linton, Melin 1982, Kent 1985, Linton 1991, Carey 1995, Feine et al. 1998, Harvey, Bryant 2000, Amjadi-Begvand et al. 2004, Fransson 2005, Pellisé et al. 2005). These reports were unrelated to whiplash trauma, but bring into question whether patients recall TMJ symptoms correctly when assessed months or more after whiplash trauma.

Both episodic and semantic memory, the two forms of declarative long-term memory, are most likely involved in recollection of symptoms (Terry et al. 2007, Terry et al. 2008). Episodic memory is the form of memory that allows a person to recall personally experienced events and put it in a spatiotemporal context. Semantic memory includes general knowledge and facts from written information, the media etc. (Tulving 1972, Nyberg, Tulving 1996, Tulving 2002). Furthermore, it has been reported that patients are inclined to use a major event to aid their recall of time of symptom onset (Raphael, Marbach 1997). Whiplash trauma represents a major event and, as such, has been regarded as a help for the patient in dating the onset of symptoms retrospectively, at least in deciding whether or not the symptoms began with the whiplash trauma. However, it has also been proposed that a patient may unconsciously and incorrectly refer the onset date of spontaneous symptoms to the time of the whiplash trauma (Sterner et al. 2003). Whether patients' memory for symptoms remain accurate over time after whiplash trauma is to date not known, but is a prerequisite for studies relying on patients' retrospective reports regarding whiplash-induced TMJ symptoms.

Aims

The aims of this thesis were:

- I** To investigate the frequency of inaccurate recall of TMJ symptoms by patients one year after whiplash trauma.
- II** To enhance current knowledge about development and course of post-traumatic TMJ symptoms over one year in patients exposed to whiplash trauma.
- III** To determine incidence, prevalence, and progression of TMJ pathology, as assessed by MR imaging, and symptoms over 15 years in adult volunteers with and without TMJ symptoms.
- IV** To determine incidence, prevalence, and progression of TMJ pathology, verified by MR imaging, and symptoms in patients after whiplash trauma, and to compare the results with the natural course.

Materials and methods

Patients

The patients were individuals who had been involved in a rear-end car collision and admitted to the emergency department at Sundsvall Hospital, Sweden. At the emergency department, orthopedic surgeons classified the trauma-related symptoms according to the Quebec classification of WAD (Table 1) (Spitzer et al. 1995). Inclusion criteria were exposure to a well-defined cervical extension-flexion trauma, without any direct trauma to the head or neck, and signs and symptoms corresponding to WAD grades 1 through 3.

During 18 months from 1994-1996, 64 consecutive patients met these criteria and were asked to participate in the project. Two patients could not undergo MR imaging due to claustrophobia and one could not undergo MR imaging during the acute phase. One patient declined to participate. The patient group at inception was comprised of 60 individuals (37 women, 23 men; mean age, 34 years; median age, 35 years; range, 16-55 years).

Figure 2 shows the participation throughout the project and reasons for not continuing participation. At the one-year follow-up, 59 patients participated (II). Forty patients reported previous or current TMJ symptoms at inception, one-year follow-up, or both (I). At the 15-year follow-up, 57 patients (95%) agreed to participate (36 women, 21 men; mean age, 49 years; median age, 50 years; range, 31-71 years) (IV).

Patients were followed up after one year (mean, 16 months; median, 15 months; range, 13-21 months) (I, II) and after 15 years (mean, 15.1 years; median, 15.3 years; range, 13.7-16.0 years) (IV).

Volunteers

Fifty-three volunteers were frequency matched by age and sex and followed the same study protocol as the patients. The volunteers represented the natural course and formed the control group. Previous direct or indirect trauma to the head or neck constituted exclusion criteria. There was no attempt to either attract or reject volunteers with TMJ symptoms in an attempt to have the volunteers reflect individuals that might be exposed to a car collision. The volunteers were recruited by word of mouth and a poster asking for volunteers to participate in a research project that would include MR imaging of the head and neck area. They came from the same geographic region as the patients.

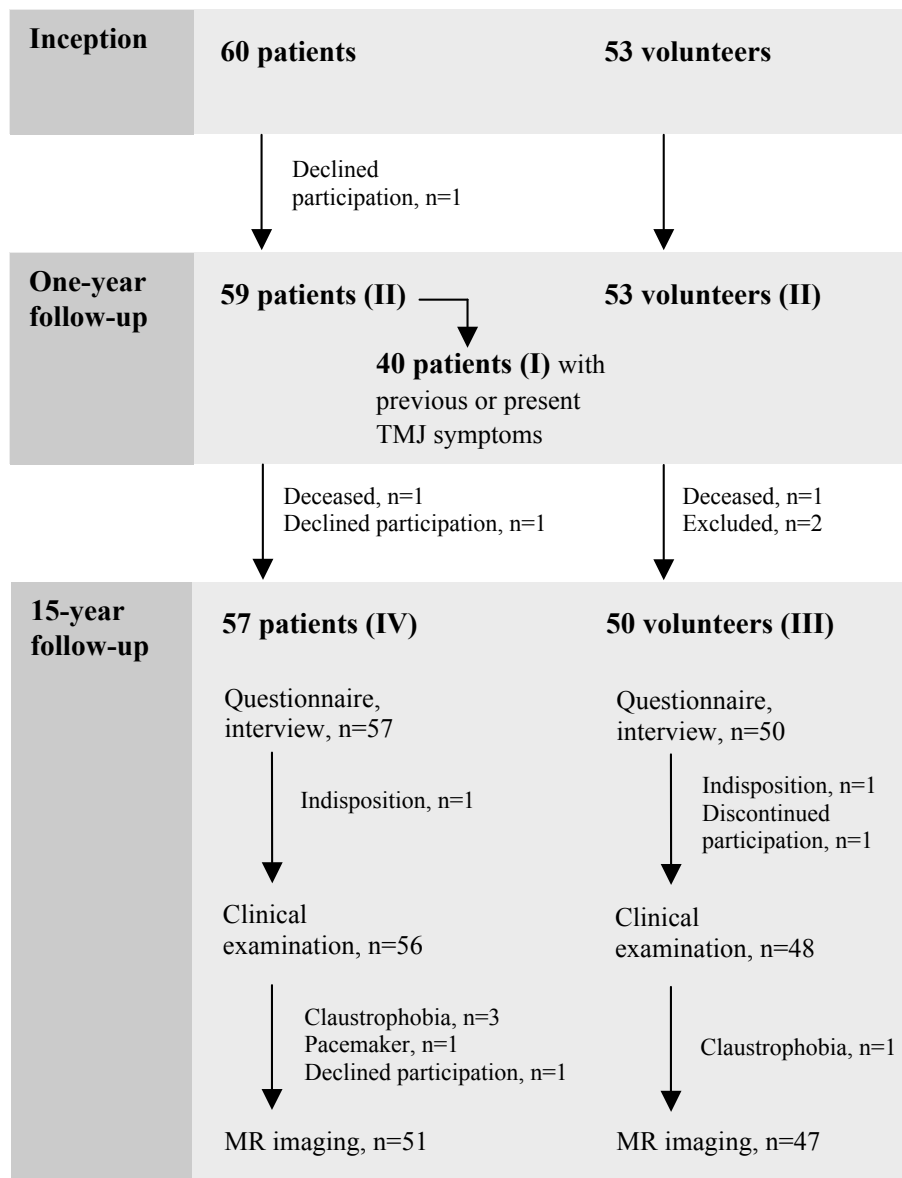


Figure 2. Number of patients and volunteers participating at inception, at one-year and 15-year follow-up, and reasons for not participating.

At inception, the control group was comprised of 31 women and 22 men with a mean age of 36 years (median age, 35 years; range 15-63 years). Figure 2 shows the participation throughout the project. All 53 volunteers participated in the one-year follow-up (II). At the 15-year follow-up, one volunteer was deceased. Two volunteers reported involvement in a car collision during the follow-up period that caused neck symptoms. They were excluded since indirect neck trauma was an exclusion criterion. The remaining 50 volunteers (94%) agreed to participate in a 15-year follow-up (30 women and 20 men, mean age, 50 years; median age, 51 years; range, 29-78 years) (III).

Volunteers were followed up after one year (mean, 14 months; median, 14 months; range, 12-17 months) (II) and after 15 years (mean, 14.2 years; median, 14.2 years; range, 13.8-14.6 years) (III).

The volunteers were subgrouped into asymptomatic and symptomatic volunteers (III). Symptomatic volunteers included those individuals reporting TMJ symptoms or having clinical TMJ symptoms, or both, at one or more examinations. Volunteers with no TMJ symptoms, either self-reported or clinical, at any of the three examinations were classified asymptomatic.

MR imaging

Bilateral MR imaging of the TMJs was performed at inception and at 15-year follow-up. Inceptive MR imaging was performed at Sundsvall Hospital, Sundsvall, Sweden, a full week (mean, 9 days; range, 3-15 days) after car collision to optimize depiction of bleeding or edema in the soft tissues. The majority at 15-year follow-up were examined in a mobile MR unit stationed at Sundsvall Hospital (Fig. 3) and some were examined at the Radiology department at Sundsvall Hospital. To maximize participation rate, we traveled to various parts of Sweden and performed MR imaging and clinical examination of patients and volunteers, who had moved out of Sundsvall, at the nearest hospital (Appendices 1, 2) (III, IV).

Protocol

The inceptive and follow-up MR examinations were performed according to the same protocol. The protocol included sagittal images in closed mouth position (T1, PD, T2 weighted images) and at wide mouth opening (PD, T2 weighted image), and coronal images in closed mouth position (PD, T2 weighted images). An axial localizer was obtained to orient the long axis of the condyle. Sagittal images were perpendicular to the long axis and coronal images were parallel to the long axis. Technical MR data is accounted for in Appendices 1 and 2.

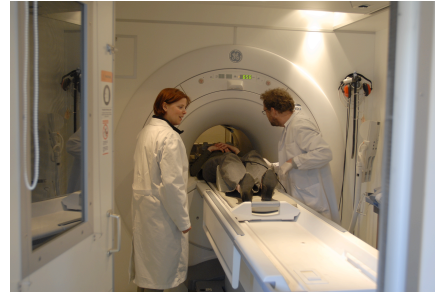

Figure 3. Examination site at Sundsvall Hospital, Sweden, at the 15-year follow-up. The field unit was comprised of a mobile MR unit and a tent with three examination rooms and one waiting room. PhD candidate and supervisor (upper left), radiographer and co-author (upper right).



Interpretation

The inception and follow-up MR images were evaluated side by side for a direct and detailed comparison of joint changes over time. The MR images were evaluated by three observers, two with many years of experience, and one with several years experience of MR images of the TMJ. The images were interpreted blinded to case history, clinical status, and whether the images were of a patient or of a volunteer.

The observers evaluated 20 bilateral TMJ MR imaging examinations (10 patients and 10 volunteers) together to establish clear definition of radiographic characteristics. The remaining 156 TMJs (41 patients and 37 volunteers) were evaluated individually and formed the basis for calculation of the inter-observer agreement. When the observers' assessments differed, consensus was reached through discussion.

The MR images were interpreted for:

- (i) *Disc position.* Classified as normative superior disc position or disc displacement according to criteria in the classification by Tasaki et al. (Tasaki et al. 1996). The displaced discs were categorized as reducing or non-reducing. The type of disc displacement was categorized as partial or complete (Larheim et al. 2001a).

(ii) *Bone status*. Classified as normative or bone changes. The bone changes included flattening, deviating form, erosion, osteophyte, sclerosis and subchondral cyst (Ahmad et al. 2009) as well as bone marrow edema, sclerosis and osteonecrosis (Larheim et al. 2001b). Flat surface that was not combined with other bone changes was considered normative.

(iii) *Joint fluid*. Classified as no effusion or effusion (Larheim et al. 2001b).

Determination of incidence or progression of TMJ pathology was based on the MR imaging examinations at inception and follow-up and defined as development of new disc displacement, aggravation of disc displacement such as reducing to non-reducing and partial to complete, development or aggravation of structural bone changes or development of joint effusion.

Clinical examination

Clinical TMJ examination was performed in association with MR imaging at inception and at 15-year follow-up. The examination protocol included palpation of the TMJs for detection of point tenderness, TMJ clickings and crepitations, and range of movement (III, IV). Two examiners performed the clinical examinations, one at inception and one at 15-year follow-up. At follow-up, another team member replaced the examiner on eight occasions.

Questionnaire and interview

Questionnaire

The same questionnaire was used at inception, the one-year and 15-year follow-up. The questionnaire was completed in connection with MR imaging at inception and the 15-year follow-up, and mailed out to the patients and volunteers at the one-year follow-up (I-IV).

The questionnaire included 38 questions that were both open-ended and multiple-choice. Health in general was covered by questions regarding health history, head and neck symptoms, medication, history of trauma and chief complaint. Question on symptoms' interference with daily life was asked with multiple choice answers of "no interference", "disturbs my sleep", "interferes with my life/studies/work", "must use analgesics", and "sick leave due to my symptoms". The participant was also asked whether he or she perceived daily living as stressful at the time of examination.

The TMJ questions concerned the following TMJ symptoms: previous and current pain, joint sounds (clicking and crepitations), transient locking and locking with restricted mandibular movement. When TMJ symptoms were reported, questions about time of onset, duration, and side of symptom location followed. The main questions were: "What is your chief complaint",

“Did the onset of your symptoms begin in association with any of the following...”, “Do you have jaw clicking”, “Have you had clicking that disappeared”, “Have you ever had limitation in jaw opening”, “Do you have limitation in jaw opening”, “Do you have jaw locking”, “Do you have pain from the jaw joint, head or jaw once a week or more often without association with eating”, “Is it painful to chew or do you experience pain after a meal”, “Is it painful to open your mouth wide, e.g. when eating a bun, a hamburger or when yawning” (translation not validated). Numerical rating scales were used for TMJ pain and ranged from 0 to 5, anchored on each end by “no pain” and “extreme pain”, respectively. The questionnaire was extended with new questions at 15-year follow-up regarding treatment received during the follow-up period and whether the participant considered seeking treatment for present symptoms.

Interview

An interview followed completion of the questionnaire on all three examinations. At inception and at 15-year follow-up the interviewer met with each patient and volunteer for the interview (I-IV). At one-year follow-up, a telephone interview was conducted (II).

The purpose of the interview was to encourage the participant to describe symptoms spontaneously, to scrutinize the answers given in the questionnaire, and to ascertain that the written answers agreed with the verbal report. When needed, the interviewer asked for clarification or more information about the participant’s symptoms such as time of onset, duration, and side of symptom location. Thus, the interview made sure the reported TMJ symptoms emanated from the joint and that the correct side was reported (right, left, or both). Furthermore, TMJ clicking should be referred to as a distinct snapping joint sound on jaw opening or closing and distinguished from crepitations (multiple grinding or scraping sounds).

The interviewer had no access to the results of MR imaging or clinical examination assessed during the ongoing examination occasion, or results from previous examinations. The interviewer was not blinded to whether the participant was a patient or volunteer since the questionnaire included information about history of trauma.

Three team members carried out the interviews; one interviewer at inception, one at one-year follow-up and one at 15-year follow-up. At 15-year follow-up, another team member replaced the interviewer on six occasions. All interviewers were calibrated prior to the onset of each examination occasion to ascertain that all interviews followed the same protocol.

Symptoms evaluated for accuracy of recall were clicking, crepitations, locking, limited mouth opening and joint pain. The patients' answers regarding symptoms and time of onset given at one-year follow-up were compared with the answers given at inception. If the answers at follow-up did not agree with the inception answers, the type of recollection error was identified according to four categories: addition of symptoms, omission of symptoms, backward telescoping and forward telescoping (Raphael, Marbach 1997, Harvey, Bryant 2000). Backward telescoping was defined as inaccurately recalling the onset of symptoms as being earlier than it actually was, i.e. having started either at the time of whiplash trauma or before whiplash trauma. Accordingly, forward telescoping was defined as inaccurately recalling the onset of symptoms as being later than it actually was, i.e. having started either at the time of whiplash trauma or after the whiplash trauma. With these definitions, telescoping implied that the patient had made recollection errors regarding the temporal order of occurrence of whiplash trauma and onset of TMJ symptoms (I).

Further examinations

Additional examinations and questionnaires were carried out at the 15-year follow-up, but are not included in the present thesis. This data will be included in future papers within the overall project. At the 15-year follow-up, an orthopedic surgeon examined patients and volunteers including palpation, registration of cervical range of motion, neurological examination as well as a questionnaire regarding clinical manifestations of whiplash injuries. Clinical examination was performed according to the Research Diagnostic Criteria for Temporomandibular Disorders (RDC/TMD) protocol (Dworkin, LeResche 1992). The patients and volunteers filled out questionnaires regarding health-related quality of life (SF-36), grade of depression (BDI-II), Jaw-function limitation scale (JFLS) and Characteristic pain intensity (CPI).

Ethics approval

The Regional Committee on Ethics at Umeå University, Sweden, approved the study protocol. Informed consent was obtained from each patient and volunteer on all three examinations.

Statistics

The Clopper-Pearson method was used to calculate exact binomial confidence interval for the proportion of patients with inaccurate recall of TMJ symptoms (I).

Kappa statistics were used to measure agreement between the inception report of TMJ symptoms and the recall of the TMJ symptoms at one-year

follow-up. To be able to rely on retrospective reports, acceptable agreement level was set at "very good" ($\kappa \geq 0.75$) (Fleiss et al. 1969, Fleiss 1981). For the purpose of kappa analysis, patients were categorized at both examinations according to the following categories: no TMJ symptoms, previous TMJ symptoms that had disappeared, present TMJ symptoms with onset prior to accident, and present TMJ symptoms with onset directly after accident (I).

Fischer's exact test was used to test for differences in outcome proportions between genders within patient group and volunteer group (II, III, IV) as well as between asymptomatic and symptomatic volunteers (III).

Score test in conditional logistic regression, stratified by age and gender was used to test for differences in outcome proportions between patients and volunteers at one-year follow-up (II). Score test in logistic regression model adjusted for age and gender was used to test for differences between patients and volunteers at 15-year follow-up (IV). Relative risks were estimated by using odds ratios computed under conditions described above (II, IV).

McNemar's test (II) and Wilcoxon signed-rank test (III, IV) were used to test for differences in outcome proportions within groups between examinations.

Kappa statistics were used to measure inter-observer agreement. Values were interpreted using guidelines of Landis and Koch (Landis, Koch 1977) adapted by Altman (Altman 1991) (≤ 0.20 , poor; 0.21-0.40 fair; 0.41-0.60, moderate; 0.61-0.80, good; 0.81-1.00, very good). The following categories were used for kappa statistics: disc position, normative superior or displaced; structural bone conditions (condyle and temporal bone together), normative or deviant; joint fluid, effusion or no effusion (III, IV).

Reported p-values (significance level = 0.05) were based on two-sided tests.

Results

After 15 years, all but one patient had settled their claims with the insurance company regarding the car collision at inception (IV).

Memory of TMJ symptoms after whiplash trauma

The calculated agreement between patients' report of TMJ symptoms at inception and their recall of the TMJ symptoms at the one-year follow-up yielded a κ value of 0.41 (95% CI 0.18-0.64). Inaccurate recall was observed

in 16/40 patients (40%) (95% CI 25-57%) by means of TMJ clicking or crepitations (n=11), locking or limited mouth opening (n=3), and TMJ clicking or crepitations in combination with locking or limited mouth opening (n=2). Figure 4 shows the recollection errors (I).

At inception, nine patients reported onset of mild TMJ symptoms directly after the whiplash trauma. Four of them recalled their symptoms inaccurately after one year (omission, n=3; backward telescoping, n=1). At the one-year follow-up, seven patients incorrectly referred symptom onset to the time of whiplash trauma (I).

TMJ symptoms

TMJ symptoms and TMJ pain as a separate symptom entity are accounted for in Figures 5 and 6. The prevalence of TMJ symptoms reported by patients to be present prior to whiplash trauma did not differ statistically from the inceptive prevalence in volunteers. Nine (15%) patients had an immediate post-traumatic onset of symptoms, which resulted in a significantly higher prevalence of TMJ symptoms at inception than prior to whiplash trauma (II). This prevalence remained significantly higher compared with before whiplash trauma throughout the study period (IV). During the first year after whiplash trauma, patients had a five times higher incidence of TMJ symptoms compared with volunteers. Of the 32 patients who were asymptomatic at inception, the incidence of TMJ symptoms was 34% compared with 7% of the 43 primarily asymptomatic volunteers (p=0.009) (II).

When TMJ pain was analyzed as a separate symptom entity, the prevalence in patients was significantly higher at one-year and 15-year follow-up compared with the prevalence prior to whiplash trauma (II, IV).

The prevalence of TMJ symptoms was significantly higher in patients compared with volunteers from inception throughout the study period. The same was observed for TMJ pain, as a separate symptom entity (II, IV).

One of five patients reported TMJ symptoms to be their main complaint at one-year follow-up (11/59 (19%)) and thereby differed significantly from volunteers (3/53 (6%)) (p=0.04). No such difference was observed at inception. Scrutiny of the type of symptoms at one-year follow-up revealed development of locking and pain in 8/11 patients with TMJ symptoms as the main complaint (II).

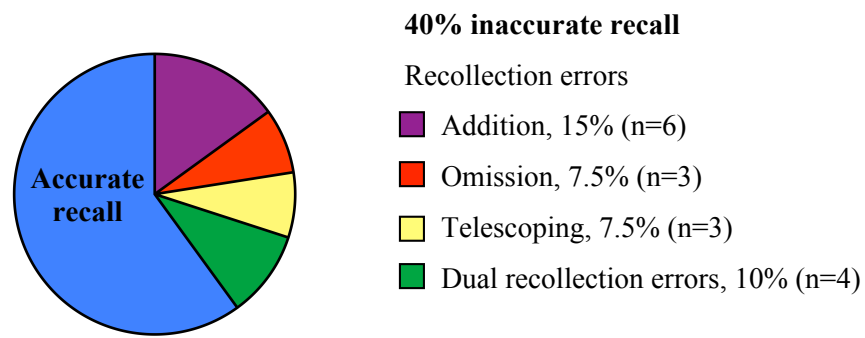


Figure 4. Frequency of patients' accurate and inaccurate recall of TMJ symptoms one year after whiplash trauma and distribution of the recollection errors.

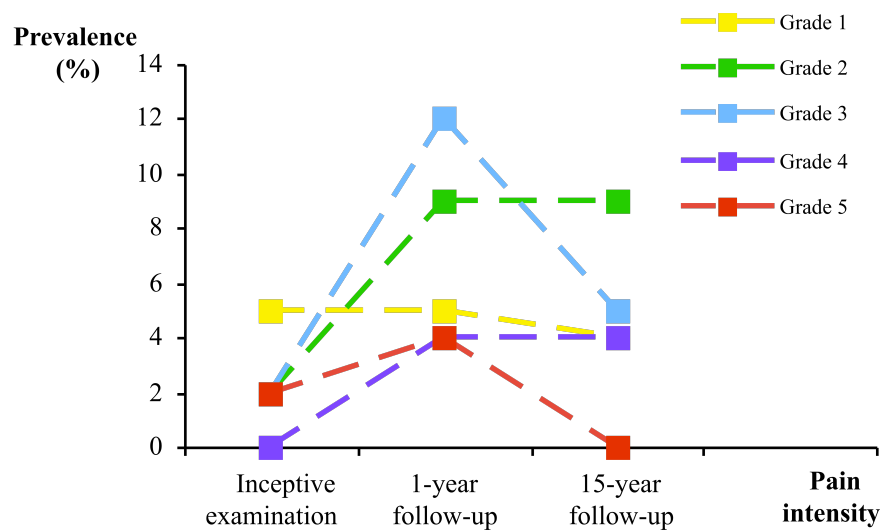


Figure 5. Prevalence of patients reporting TMJ pain at the three examination occasions plotted against a numerical scale for intensity of pain. The rating scale was from 0 = "no pain" to 5 = "extreme pain".

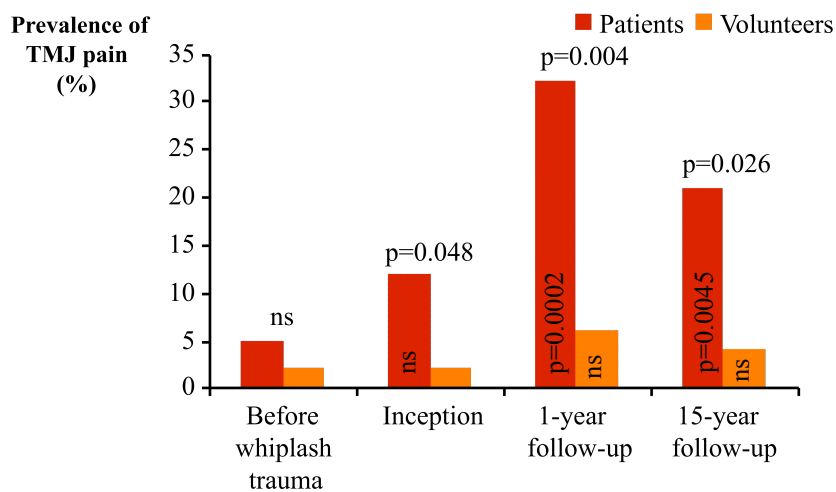
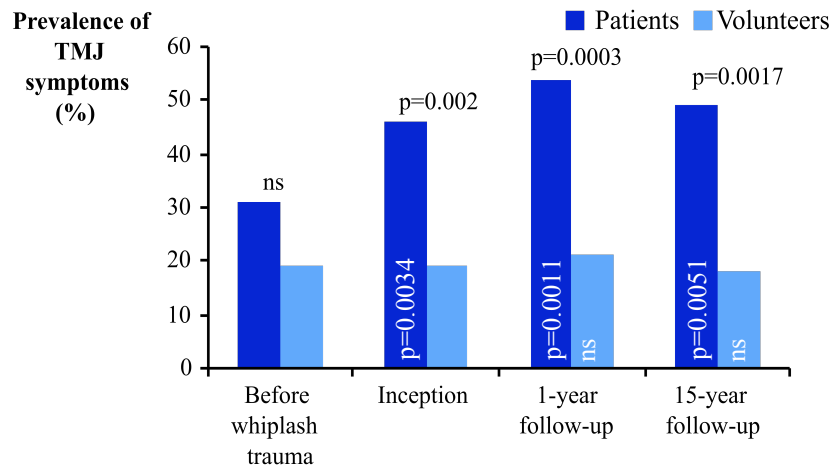


Figure 6. Prevalence of (a) TMJ symptoms (pain dysfunction, or both) and (b) TMJ pain as a separate symptom entity in patients and volunteers over the 15-year follow-up study period. At inception and one-year follow-up, 59 patients and 53 volunteers participated. At 15-year follow-up, 57 patients and 50 volunteers participated.

P-values given above columns show comparisons between groups at each examination. P-values given within columns show comparisons with status before whiplash trauma within groups. Comparison between 15-year follow-up and before whiplash trauma are based on the 57 patients and 50 volunteers participating throughout the study period. ns = no significance.

Gender aspect

Female patients had a significantly higher prevalence of TMJ symptoms throughout the 15-year study period compared with the reported prevalence prior to whiplash trauma, whereas the corresponding comparison for male patients revealed a significantly higher prevalence only at one-year follow-up (II, IV).

Prevalence of TMJ pain was significantly higher in both female and male patients at the one-year follow-up compared with the reported prevalence prior to whiplash trauma and remained significantly higher in male patients at the 15-year follow-up (II, IV).

The number of female patients reporting TMJ symptoms to be their main complaint was significantly higher at one-year follow-up compared with inception, whereas male patients did not differ between examinations (II).

TMJ treatment during the study period

No patient received treatment due to TMJ symptoms during the first year following whiplash trauma. At one-year follow-up, seven patients spontaneously expressed a need for TMJ treatment. The patients had complained about their TMJ symptoms to their orthopedic surgeons, physical therapists or dentists, but treatment had been focused only on neck treatment and no TMJ treatment had been undertaken. At 15-year follow-up, five patients reported the use of an occlusal splint due to TMJ symptoms (n=1) and bruxism (n=4), and three volunteers due to bruxism. Three patients expressed a need for TMJ treatment. No volunteer considered treatment to be necessary at any of the three examinations (II-IV).

Analgesics were used daily by 42% of patients at inception, 10% at one-year follow-up and 9% at 15-year follow-up, and occasionally by 10% of patients at inception, 27% at one-year follow-up and 28% at 15-year follow-up. Analgesics were used occasionally by 6% of volunteers at inception and one-year follow-up, daily by 4% and occasionally by 18% at 15-year follow-up (II, IV).

MR imaging findings

Inception

At inception, none of the patients demonstrated any MR imaging signs of acute TMJ injuries such as bleeding or edema in soft tissues. Patients and volunteers did not differ statistically regarding prevalence of any TMJ

pathology except for structural bone changes, which was significantly more prevalent in patients compared with volunteers (Table 2) (IV).

Symptomatic volunteers had a significantly higher prevalence of disc displacement compared with asymptomatic volunteers (16/18 (89%) versus 9/29 (31%)) ($p=0.0002$), but there were no differences between groups in type of disc displacement (partial or complete). Effusion was observed in TMJs with disc displacement and present in seven symptomatic TMJs and in seven asymptomatic TMJs. Structural bone changes were observed in one symptomatic TMJ. In volunteers, a female preponderance of disc displacement was observed (III).

15-year follow-up

Follow-up MR imaging revealed that patients and volunteers did not differ statistically in incidence and progression of TMJ pathology (IV).

Incidence or progression was observed in 8/102 (8%) TMJs in 6/51 (12%) patients, all being women. Four TMJs in three symptomatic patients had disc-related incidence or progression (Table 3a). One of these patients developed an additional alteration in condyle shape. Incidence of structural bone changes solely was observed in four TMJs in three asymptomatic patients, all appearing in the condyle in TMJs with disc displacement. The bone changes consisted of erosion ($n=2$), subcortical sclerosis ($n=1$), and alteration in condyle shape with maintained cortical outline ($n=1$). There were no gender differences regarding prevalence of TMJ pathology (IV) Figures 7 and 8 illustrate maintenance and progression of TMJ status, respectively, over the 15-year study period.

At 15-year follow-up, TMJ pain was not associated with TMJ disc displacement in patients. Five of the 12 patients reporting TMJ pain had disc displacement and five had bilateral superior disc position. Two could not undergo follow-up MR imaging; one of which had bilateral superior disc position and the other had unilateral disc displacement at inception (IV).

Incidence or progression was observed unilaterally in 4/47 (9%) volunteers (4/94 (4%) TMJs), out of whom three were women. The incidence or progression was disc-related in one asymptomatic and one symptomatic volunteer (Table 3b). Incidence of structural bone changes was observed in two asymptomatic volunteers; in one seen as a concavity on the superior surface of the condyle in a TMJ with normative superior disc position, and in the other seen as a concavity on the supero-posterior aspect of the condyle in a TMJ with reducing disc displacement and effusion (III).

Study sample	INCEPTIVE EXAMINATION				15-YEAR FOLLOW-UP			
	Patients No. (%)	Control subjects No. (%)	Patients versus Control subjects (P-value) [†]	OR* 95% CI [§]	Patients No. (%)	Control subjects No. (%)	Patients versus Control subjects (P-value)	OR 95% CI
Joints	n=102	n=94			n=102	n=94		
DD	51 (50%)	39 (41%)	ns	1.33 0.72-2.46	52 (51%)	40 (43%)	ns	1.29 0.70-2.38
-DDR	38 (37%)	32 (34%)	ns	1.18 0.61-2.26	37 (36%)	32 (34%)	ns	1.12 0.58-2.15
-DDNR	13 (13%)	7 (7%)	ns	2.21 0.72-6.80	15 (15%)	8 (9%)	ns	2.17 0.74-6.33
-Partial	20 (20%)	17 (18%)	ns	0.98 0.44-2.20	20 (20%)	18 (19%)	ns	0.90 0.40-2.00
-Complete	31 (30%)	22 (23%)	ns	1.66 0.80-3.47	32 (31%)	22 (23%)	ns	1.68 0.81-3.51
Effusion	11 (11%)	14 (15%)	ns	0.69 0.28-1.73	12 (12%)	15 (16%)	ns	0.69 0.28-1.68
Bone changes	17 (17%)	1 (1%)	0.0039	21.93 2.69-178.63	20 (20%)	3 (3%)	0.0024	7.75 2.07-29.09
Subjects	n=51	n=47			n=51	n=47		
DD	32 (63%)	25 (53%)	ns	1.09 0.89-1.34	32 (63%)	26 (55%)	ns	1.07 0.87-1.30
-Unilateral	13 (25%)	11 (23%)	ns	1.11 0.86-1.42	12 (24%)	12 (26%)	ns	1.05 0.82-1.35
-Bilateral	19 (37%)	14 (30%)	ns	1.08 0.86-1.37	20 (39%)	14 (30%)	ns	1.08 0.85-1.36
[†] P values based on score test in conditional logistic regression				[§] CI, Confidence interval				
OR, Odds ratio				DD, disc displacement with reduction (DDR) or without reduction (DDNR)				

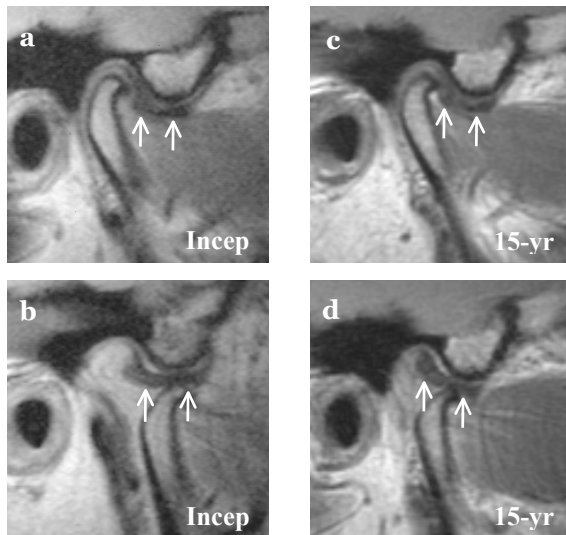


Figure 7. Maintained anterior TMJ disc displacement with reduction (arrows) from inception to 15-year follow-up. PD-weighted sagittal MR images in (a) closed mouth and (b) open mouth position at inception, and (c) closed mouth and (d) open mouth position at 15-year follow-up.

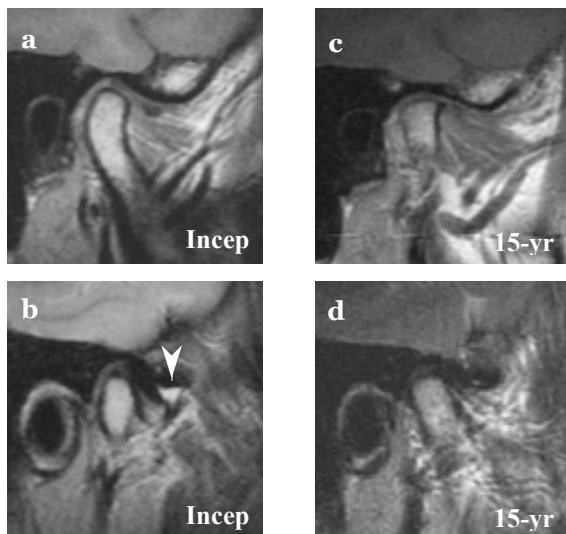


Figure 8. Progression of TMJ pathology. Sagittal MR images at inception in closed mouth position in (a) PD-weighted image from central part of TMJ and (b) T2-weighted image from lateral part of TMJ showing displaced disc with effusion (arrowhead). Corresponding images at 15-year follow-up (c - d) showing progression of disc displacement and change of condyle shape. The patient reported clicking, locking and pain at one-year follow-up.

Table 3a. PATIENTS. TMJ disc position verified by MR imaging in 104 TMJs at 15-year follow-up versus inception			
Inception	15-year follow-up		
	Superior disc position (n=50)	DDR (n=37)	DDNR (n=15)
Superior disc position (n=51)	50	0	1
DDR (n=38)	0	37†	1
DDNR (n=13)	0	0	13‡
DDR = disc displacement with reduction, DDNR = disc displacement without reduction. † Progression in one TMJ by means of further displacement of the disc and addition of effusion. ‡ Progression in one TMJ from partial to complete DDNR. ■ TMJs with maintained disc position at 15-year follow-up.			

Table 3b. VOLUNTEERS. TMJ disc position verified by MR imaging in 94 TMJs at 15-year follow-up versus inception			
Inception	15-year follow-up		
	Superior disc position (n=54)	DDR (n=32)	DDNR (n=8)
Superior disc position (n=55)	54	1	0
DDR (n=32)	0	31	1
DDNR (n=7)	0	0	7
DDR = disc displacement with reduction, DDNR = disc displacement without reduction. ■ TMJs with maintained disc position at 15-year follow-up.			

Between follow-ups one patient was diagnosed with rheumatoid arthritis, one patient and one volunteer with sarcoidosis, and three patients reported involvement in a second car collision. The collision caused neck symptoms but no immediate TMJ symptoms. At 15-year follow-up none of these five patients or the volunteer had additional MR imaging findings, or any additional TMJ symptoms compared with the one-year follow-up. One patient and one volunteer were diagnosed with fibromyalgia between follow-ups. Progression of TMJ pathology was observed in the patient, and both had development of TMJ pain during the corresponding period (IV).

Participants who did not undergo follow-up MR imaging

Inceptive TMJ disc positions and symptom status in patients and volunteers who could not undergo follow-up MR imaging examination, or did not participate at 15-year follow-up, are accounted for in Table 4 (III, IV).

The two volunteers who were excluded due to indirect neck trauma following a car collision were fully examined at the 15-year follow-up. One of them was asymptomatic at inception and had reducing disc displacement in one TMJ and non-reducing displacement in the contra-lateral TMJ. At 15-year follow-up, the reducing disc displacement had progressed to non-reducing and symptomatic. The other volunteer was asymptomatic and had inceptive unilateral reducing disc displacement. At 15-year follow-up, no development or aggravation of TMJ pathology was observed, but bilateral TMJ pain was reported. The time of onset of TMJ symptoms relied on the patients' recall and, hence, temporal order of car collision and onset of TMJ symptoms could not be determined (III).

Table 4. Inceptive TMJ disc position and symptoms in patients and volunteers who did not undergo MR imaging or did not participate (the latter in parenthesis) at 15-year follow-up				
	Patients		Volunteers	
	Asymptomatic	Symptomatic	Asymptomatic	Symptomatic
Superior	2	1	1	(1)
Unilateral DD*	2	(1)	1	(1†)
Bilateral DD	1	(2)	1	(1†)
* DD, disc displacement.				
† Excluded due to whiplash trauma during follow-up period.				

Inter-observer agreement

The inter-observer agreement of the three observers was very good. The kappa value for disc position was 0.95, structural bone changes 0.97, and joint effusion 0.95 (IV).

Discussion

This prospective longitudinal study demonstrated that recollection of TMJ symptoms was often inaccurate one year after whiplash trauma, implying that a prospective study design is a requirement for valid long-term follow-up after whiplash trauma (I). The whiplash trauma induced immediate mild temporomandibular symptoms in 15% of patients. During the first year following whiplash trauma, one of three primarily asymptomatic patients developed new TMJ symptoms (II). TMJ symptoms were significantly more prevalent in patients throughout the 15-year study period compared with the prevalence reported to be present prior to whiplash trauma, as well as compared with matched volunteers. There was, however, no statistically significant difference in incidence, prevalence or progression of TMJ pathology between groups as verified by MR imaging (IV). The prevalence of disc displacement was significantly higher in volunteers with TMJ symptoms than in asymptomatic volunteers, but the 15-year natural course disclosed a low incidence and progression of TMJ pathology in all volunteers, that is those with and those without TMJ symptoms (III).

Methodological considerations

The patients in this prospective study were consecutive patients who had been admitted to a hospital emergency department because of neck symptoms after a rear-end car collision. This material sampling method has been stated to result in the most representative sample (Barnsley et al. 1994). Police and paramedics often urge individuals involved in traffic collision to go to the hospital emergency department for examination of potential injuries. This contributes to a spread of symptoms to cover the symptom spectrum from mild to severe, which was the case also in this study.

Examining the patients directly after whiplash trauma enabled identification of acute injuries to the TMJs such as bleeding or edema in soft tissues, and provided a valid baseline status both regarding joint pathology and symptoms. The control group of matched volunteers examined concurrently was aimed to reflect a general population who might be exposed to whiplash trauma. These factors were a prerequisite for investigating TMJ sequelae following whiplash trauma.

The participation rate was high for patients and volunteers at both follow-ups, and the bias caused by attrition was small. The subgroups within patients and volunteers were small, but benefited from the high participation rates.

It is a general belief that legal processes concerning injury compensation have a negative impact on health status. A recent systematic meta-review challenged this perception, since the only high-quality systematic review found showed evidence of no association between litigation and poor health outcomes in patients with whiplash-associated disorders (Spearing, Connelly 2011). In Sweden, the national health care insurance covers health care costs for patients with whiplash injuries and litigation is rare. Hence, damage does not constitute an economic incentive for patients in Sweden to overestimate symptoms after whiplash trauma. All but one patient in the present study had settled their claims with the insurance company. When damages had been paid, they were small.

The TMJ status was verified by MR imaging at inception and at follow-up, which allowed for determination of incidence and progression of TMJ pathology in patients and volunteers over 15 years. The same MR imaging protocol was used for both examinations. A radiologist made sure that the long axis of the condyle was correctly aligned during imaging. A small number of MR imaging examinations were carried out with no radiologist present at the 15-year follow-up, but the same trained radiographic nurse who had carried out all the inception MR imaging examinations performed these examinations. This contributed to comparable MR images, which was a requirement for identification of TMJ changes in each individual over time. Agreement of long axis alignment between examinations was confirmed when intra-individual inception and follow-up images of each individual were analyzed side by side.

Patients had a higher prevalence of structural bone changes than volunteers. The majority of bone changes in patients were minor sclerosis on the condyle with no TMJ pain. At 15-year follow-up, these bone changes had not progressed and were still not associated with TMJ pain. Hence, the higher prevalence in patients did not plausibly affect progression of TMJ pathology or prevalence of TMJ symptoms during the study period.

Treatment with occlusal splint may have had a favourable impact on the TMJ disc status. But the number of patients and volunteers using occlusal splints during follow-up was similar (5 patients, 3 volunteers) and was, therefore, unlikely to have had any significant effect on the difference between groups regarding incidence and progression of TMJ pathology. One

of the volunteers who used a splint had unilateral disc displacement with reduction at both MR imaging examinations and the inceptive painful clicking and locking had ceased at 15-year follow-up. Even though the splint was not intended as treatment for the symptomatic TMJ, a beneficial effect cannot be ruled out.

The same questionnaire and interview protocols were used for all three examinations. When symptoms were reported, the interviewer asked the patient or volunteer to point out the area from where the symptoms emanated. Particular caution was paid to only include symptoms emanating from the TMJ site in order to avoid overestimation of TMJ symptoms. The interviewers at inception and the two follow-ups were trained and followed the same interview protocol. Hence, the patients and volunteers were interviewed in the same way on all three examinations. The interviewers did not have access to data from previous or present examinations except for history of whiplash trauma given in the questionnaire. Items in the questionnaire covered areas included in the RDC/TMD (Dworkin, LeResche 1992), but the RDC/TMD examination method was not used at inception since the onset of this research project coincided with the introduction of RDC/TMD.

Memory of TMJ symptoms after whiplash trauma

Inaccurate recollection of TMJ symptoms one year following whiplash trauma was common (I). This finding is in accordance with previous studies reporting inaccurate recall of symptoms in various body regions (Raphael, Marbach 1997, Linton, Melin 1982, Kent 1985, Linton 1991, Carey et al. 1995, Feine et al. 1998, Harvey, Bryant 2000, Amjadi-Begvand et al. 2004, Fransson 2005, Pellisé et al. 2005). The recollection period in these latter studies was three weeks or more. A recollection period of up to two weeks, on the other hand, resulted in accurate recall of symptoms (Hunter et al. 1979, Singer et al. 2001, Bryant et al. 2006). The lapse of time from whiplash trauma to inceptive questionnaire and interview did not surpass two weeks for the patients in this study (I), and the baseline data are therefore considered reliable.

Even though a common recollection error was referral of TMJ symptoms to the time of whiplash trauma, these patients are most likely correct regarding cause and effect, that is, the whiplash trauma induced their symptoms, because there was a high incidence of delayed TMJ symptoms during the year following the whiplash trauma (II).

The high inaccuracy of recall of TMJ symptoms after whiplash trauma demonstrates the necessity of a prospective study design for investigation of TMJ sequelae following whiplash trauma. Examinations carried out in close

proximity to whiplash trauma provide an accurate baseline status at time of whiplash trauma, which is a requirement for valid long-term evaluations. A further consequence of the inaccurate recall of symptoms is that previous studies on TMJ sequelae after whiplash trauma that relied on patients' recollection of symptoms should be interpreted with considerable caution. These studies enrolled patients months or even more than a year after whiplash trauma based on the patients' report that they had no TMJ symptoms prior to the collision. The inaccurate recall of TMJ symptoms raises a concern regarding temporal order of onset of TMJ symptoms versus whiplash trauma in such studies and, in consequence, the relevance of the conclusions drawn.

TMJ sequelae after whiplash trauma

The whiplash trauma induced immediate onset of TMJ symptoms in 15% of our patients, who are considered representative of patients exposed to whiplash trauma (II). This presumption was supported by the results of a population-based study, which reported that 15.8% of subjects with whiplash-associated disorders had new onset of impaired and/or painful jaw movement after car collision (Carroll et al. 2007). When patients exposed to whiplash trauma were examined two weeks after car collision, a significantly higher TMJ pain, muscle tenderness and limited mouth opening was observed in these patients compared with a matched control group (Kronn 1993). In our study, a significantly higher prevalence of TMJ pain in patients compared with matched volunteers at inception was observed, which concur with these results (II).

Whereas TMJ symptoms can be induced by whiplash trauma, no MR imaging findings of acute TMJ injuries was observed directly after whiplash trauma. Most of the initially displaced TMJ discs were deformed, which indicates that the disc displacement was present prior to the whiplash trauma. Effusion was not observed in the TMJs with disc displacement without disc deformation, which would have been expected had the whiplash trauma induced the disc displacement (Bergman et al. 1998). Taking into account that patients and volunteers did not differ significantly in prevalence of disc displacement either at inception or 15 years later (IV) makes whiplash-induced disc displacement most improbable. The previously claimed relationship between whiplash trauma and TMJ disc displacement was therefore contradicted (Weinberg, LaPointe 1987, Pressman et al. 1992, Garcia, Arrington 1996). The claimed relationship was based on a high prevalence of TMJ disc displacement observed in patients with TMJ symptoms and a history of whiplash trauma. The studies were limited by lack of a control group. Their reported prevalence of disc displacement after whiplash trauma was equally high in patients with TMJ symptoms but no specific history of

whiplash trauma (Tasaki et al. 1996, Katzberg et al. 1996, Larheim et al. 2001a). Another limitation was relying on patients' retrospective reports given months after the collision of a post-traumatic onset of TMJ symptoms, which often appeared to be inaccurate in the present study (I).

The follow-ups revealed that whiplash trauma can induce TMJ symptoms during the first year after car collision (II), but also that TMJ sequelae can persist long-term (IV). A high incidence of TMJ symptoms was observed after one year and one of five patients reported TMJ symptoms to be their main complaint, indicating their TMJ symptoms were quite significant for these patients. TMJ pain was significantly more prevalent in patients after one year and 15 years compared with before whiplash trauma, and compared with the natural course in volunteers. These results contradict a follow-up of patients with whiplash-associated disorders, which reported no significant difference between patients and control subjects regarding TMJ pain six months after the car collision (Kasch et al. 2002). The differing results are plausibly explained by difference in patient sampling. The latter study included patients with WAD grade 1, while our study included WAD grades 1 through 3. In addition, the two studies included different age groups. Our study had no restrictions regarding age and resulted in a range of 15 to 55 years at inception, while the latter study had an inclusion criterion of ages between 20 and 35 years.

Poor prognosis regarding neck disability and sick leave after whiplash trauma is more common in women than in men (Spitzer et al. 1995, Sterner et al. 2003, Kasch et al. 2008). As with the neck, a female preponderance has previously been reported concerning incidence of jaw pain one month after car collision (Carroll et al. 2007). In our study, female patients had a significantly higher prevalence of TMJ symptoms throughout the study period compared with the reported prevalence prior to whiplash trauma (IV). Furthermore, female patients accounted for the increase of reported TMJ symptoms, which constituted the main complaint after one year (II). Incidence and progression of TMJ pathology occurred only in female patients (IV).

One of five patients reported TMJ pain at the 15-year follow-up, which was five times more prevalent than in volunteers. Half of these patients had disc displacement, which may be a reason for the pain. The other half had bilateral superior disc position and MR imaging did not reveal any plausible cause of pain. The whiplash patients hereby differed from patients seeking treatment for TMJ symptoms since a 77-82% prevalence of disc displacement has been reported for TMJ patients (Tasaki et al. 1996, Katzberg et al. 1996, Kahn et al. 1998, Larheim et al. 2001a). Absence of MR imaging findings,

however, does not exclude the possibility of pathology intra-articularly or adjacent to the joint.

An analogy can be drawn between TMJ and neck, since standard MR imaging commonly failed to reveal cause of neck symptoms after whiplash trauma (Fagerlund et al. 1995, Pettersson et al. 1997, Borchgrevink et al. 1997, Kongsted et al. 2008). In contrast to these results, postmortem studies of the cervical spine in road traffic collision fatalities have revealed subtle injuries to cervical spine facet joints that were not seen in conventional radiology, computed tomography, or MR imaging (Uhrenholt et al. 2009). Other imaging techniques may enable visualization of pathology. A recent study used positron emission tomography (PET) with the tracer [11C]-D-deprenyl, which showed signs of inflammation in upper cervical tissues in patients with persistent neck pain following whiplash trauma (Linnman et al. 2011).

Another plausible explanation for the TMJ pain in our patients includes referred pain from the cervical region to the TMJ area. Pain can be referred in this way because sensory input from the cervical and trigeminal neurons converge onto common neurons, which can be sensitized as an effect of long lasting peripheral tissue inflammation (Sessle 1999). Furthermore, recent evidence suggests that glial cells take part in the central neuronal sensitization process (Milligan, Watkins 2009, Villa et al. 2010, Zhuo et al. 2011). Thus, changes in neuron-glial interactions as a consequence of peripheral tissue damage may contribute to dysfunctional pain in some patients following whiplash injury. Functional coupling between the jaw and neck was underscored when impaired jaw and head-neck movement as well as impaired endurance during chewing was revealed in patients with whiplash-associated disorders, showing an association between neck injury and disturbed jaw function (Häggman-Henrikson et al. 2002, Häggman-Henrikson et al. 2004). A myogenous origin of the pain, which our patients reported to emanate from the TMJ, cannot be excluded although we made considerable effort to distinguish between myogenous and arthrogenous pain.

Natural course

Asymptomatic volunteers

TMJ disc displacement is present in approximately one of three asymptomatic adults (Tasaki et al. 1996, Katzberg et al. 1996, Kahn et al. 1998, Larheim et al. 2001a). This high prevalence raised the opinion that disc displacement in the TMJ is a congenital condition (de Bont et al. 1997). Contradicting evidence revealed that disc displacement is an acquired condition. An MR imaging study of infants and young children aged 2 months to 5 years revealed no case of TMJ disc displacement (Paesani et al. 1999).

The prevalence of disc displacement in individuals with asymptomatic TMJs increases with age from childhood throughout adolescence (Fig. 9). In line with these findings, a previous MR imaging follow-up study revealed a high incidence of TMJ disc displacement in asymptomatic adolescents and the results also pointed to a chronic nature of disc displacement (Tominaga et al. 2007).

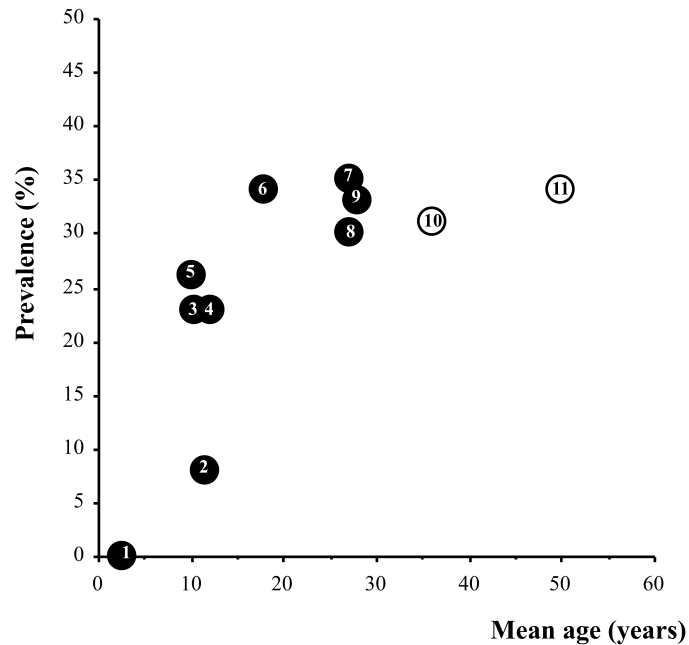


Figure 9. Prevalence of disc displacement according to age in asymptomatic volunteers. Prevalence from different age groups extracted from other studies and from the present study (mean age presented here, except for reference 6, which has median age reported). References: 1) Paesani et al. 1999, 2) Hans et al. 1992, 3) Masi et al. 2009, 4) Tominaga et al. 2007, 5) Kecik et al. 2004, 6) Ribeiro et al. 1997, 7) Larheim et al. 2001a, 8) Tasaki et al. 1996, 9) Katzberg et al. 1996, 10) results from inception in this study, 11) results from 15-year follow-up in this study.

One-third of the asymptomatic adult volunteers had disc displacement at inception (III), which is in agreement with the prevalence previously reported for asymptomatic adults (Tasaki et al. 1996, Katzberg et al. 1996, Kahn et al. 1998, Larheim et al. 2001a). After a natural course of 15 years, the prevalence of disc displacement remained approximately the same due to a low incidence of disc displacement and lack of normalization of any of the initially

displaced discs (III). Hence, the prevalence of disc displacement increases with age up to young adulthood, after which the prevalence seems to level off (Fig. 9).

Symptomatic volunteers (non-patients)

The prevalence of TMJ disc displacement in symptomatic non-patient volunteers was the same as previously reported in patients seeking treatment for TMJ symptoms, and the prevalence differed significantly from that in asymptomatic volunteers (Tasaki et al. 1996, Katzberg et al. 1996, Kahn et al. 1998, Larheim et al. 2001a) (III). But incidence and progression of TMJ pathology in the symptomatic volunteers was as low as in the asymptomatic volunteers (III), thereby contrasting with the considerably higher progression previously reported for patients (Lundh et al. 1987, Westesson, Lundh 1989).

Although symptomatic volunteers and patients seeking treatment for TMJ symptoms have the same magnitude of disc displacement, the two groups differ in that patients more often have bilateral displacement than symptomatic volunteers (III). This may reflect a possible systemic factor in patients such as deviant collagen composition, general joint laxity as well as hormonal factors (Johansson, Isberg 1991, Westling, Mattiasson 1992, Westling et al. 1992, Abubaker et al. 1993, Ribeiro-Dasilva 2009).

The implication of the findings in this study is pertinent to study design of future controlled studies of TMJ pathology. There is a risk of biased results and conclusions if comparisons are made between TMJ patients and asymptomatic volunteers solely, without taking symptomatic volunteers into account. An association between TMJ disc displacement and TMJ pain and dysfunction has previously been concluded based on comparisons between patients with TMJ symptoms and asymptomatic volunteers (Tasaki et al. 1996, Katzberg et al. 1996, Larheim et al. 2001a). This conclusion might be questioned because the symptomatic volunteers in our study demonstrated a high prevalence of disc displacement, which was not associated with pain. Therefore, future controlled studies should include symptomatic and not just asymptomatic volunteers as control groups when investigating TMJ pathology in patients.

Indications for treatment

None of the symptomatic volunteers felt a need for treatment, indicating that their TMJ symptoms were mild. The stable TMJ status observed in the vast majority of adult volunteers with no TMJ symptoms or mild TMJ symptoms over the 15-year study period, points to no or little indication for treatment of these two groups, whereas disc displacement associated with severe symptoms in patients requires treatment. This conclusion refers to adults and

should not be translated to children and adolescents. Treatment indications for children and adolescents should be put in a broader context because of the high incidence of asymptomatic and symptomatic disc displacement in late childhood and adolescents (Tominaga et al. 2007, Isberg et al. 1998), in combination with the adverse effect exerted on facial growth by disc displacement, whether asymptomatic or symptomatic (Nebbe et al. 1998, Isberg, Legrell 2000).

Future aspects

This research project embraces areas that were beyond the scope of this thesis but will be investigated such as neck status, jaw function, health-related quality of life, grade of depression, and possible relationships between these factors.

Conclusions

This prospective 15-year follow-up study concludes that future studies on TMJ sequelae following whiplash trauma should be prospective in study design with examinations conducted in close proximity to whiplash trauma. This allows for reliable baseline status and potential bias of inaccurate recall of symptoms is minimized.

Future controlled studies on TMJ pathology in patients should include control groups of not only asymptomatic but also symptomatic volunteers in order to avoid potentially biased conclusions.

One of three patients exposed to whiplash trauma can be expected to develop TMJ symptoms beyond that which corresponds to the natural course in volunteers. This finding and previously reported impairment of jaw function in patients with symptoms after whiplash trauma points to the need for including TMJs and related muscles in routine medical examinations of patients with symptoms following whiplash trauma.

Adult individuals presenting with no or mild TMJ symptoms seldom show development or aggravation of TMJ pathology and there is no or little indication for TMJ treatment of these adult individuals. This is in contrast to the higher progression of TMJ pathology previously reported for adult patients with TMJ symptoms, which requires treatment.

Acknowledgements

This thesis would not have been possible without the help and commitment of many persons. My sincere gratitude in particular to:

Professor Annika Isberg, principal supervisor and co-author throughout this project. You have communicated guidance and advice with enormous enthusiasm and thoroughness, and have always generously shared your profound knowledge of TMJ and radiology.

Dr Fredrik Bryndahl, co-author on papers III and IV, for sharing your scientific knowledge, clear-sighted thoughts, and clinical skills. Thank you for the excellent drawing and layout of front cover of this thesis.

Professor Leif Hedman, co-author on paper II, for sharing your knowledge of memory.

Dr Christer Hildingsson, for cooperation in data collection during the 15-year follow-up, and for encouragement, advice, and valuable discussions.

Dr Henrik Bergman, whose extensive efforts concerning data collection at inception laid the foundation of the subsequent follow-up studies in this thesis.

Dr Fredrik Wiklund for statistical advice and analyses in all papers.

Lillemor Hägglund, Department secretary, for never-ending encouragement, exceptional administrative assistance, and personal consideration during all these years.

Roine Backlund, Head of facilities, Landstingsservice, Sundsvall Hospital, for practical arrangements prior to the 15-year follow-up, in particular with installation of the mobile MR unit and set-up of examination rooms.

Jessica den Hoed, radiographer, and Peter Hägglund, medical engineer, for invaluable technical help with the mobile MR unit.

Professor Lars Eriksson for critical review and constructive critique of papers II-IV.

Dr Per Erik Legrell, for proof reading of this thesis, constructive comments, and help with practical matters prior to the 15-year follow-up.

Dr Marcelo Kreiner, for valuable comments in paper IV and encouragement.

Ulrika Bertilsson, Research Engineer, for valuable help with figures in paper II, technical help whenever needed and encouragement.

Alyce Norder for expert editing of the English text.

Pia Lundgren, Secretary at Department of Orthopedics, for great help with practical matters during our examination days at Sundsvall Hospital.

Magnus Johansson for kind support during this project.

Professor Sven-Ola Hietala for advice and support.

Dr Eva Levring Jäghagen, Dr Tore Nilsson and Dr Jan Ahlqvist for encouragement during this project.

Gunnar Siegel for help with practical matters and for encouragement.

The staff at Radiology department at Sundsvall Hospital, and in particular Liselott Mafi, Ann Mari Svedberg, and Agneta Nilsson, for carrying out MR imaging examinations at the hospital.

The staff at Uppsala University Hospital, Medicinsk Röntgen in Stockholm, Stockholm South General Hospital, Xyrinx Medical Imaging in Gothenburg, and Östersund Hospital for carrying out MR imaging examinations at the 15-year follow-up.

The staff at Oral and Maxillofacial Radiology, Umeå University, for always welcoming me at the department.

The staff at Oral and Maxillofacial Radiology, Malmö University, for great support and encouragement while I have been working on this project.

I would also like to thank all patients and volunteers who generously participated in this study.

To my family,
Sebastian, for your love, patience and endless encouragement.
Märtha and Leah, for your love and happiness.

My parents Elenor and Carl Gustaf, for being supportive in every way.
My sister Sofia, for encouragement and for always being there.

To my family in-law, Ann, Lars-Erik, and Hampus, for support.

Supported by grants from Umeå University, the County Council of Uppsala, Folksam, the Swedish Association for Survivors of Accident and Injury, Sigrid de Verdier's Foundation, and Carl O. Henrikson Foundation, Sweden.

References

- Abubaker AO, Raslan WF, Sotereanos GC. Estrogen and progesterone receptors in temporomandibular joint discs of symptomatic and asymptomatic persons: a preliminary study. *J Oral Maxillofac Surg* 1993;51:1096-1100.
- Ahmad M, Hollender L, Anderson Q, et al. Research diagnostic criteria for temporomandibular disorders (RDC/TMD): development of image analysis criteria and examiner reliability for image analysis. *Oral Surg Oral Med Oral Pathol Oral Radiol Endod* 2009;107:844-860.
- Altman DG. Some common problems in medical research. In: *Practical statistics for medical research*. First edition. London: Chapman and Hall, 1991:404.
- Amjadi-Begvand S, Khanna D, Park GS, Bulpitt KJ, Wong WK, Paulus HE. Dating the "window of therapeutic opportunity" in early rheumatoid arthritis: accuracy of patient recall of arthritis symptom onset. *J Rheumatol* 2004;31:1686-1692.
- Barnsley L, Lord S, Bogduk N. Whiplash injury. *Pain* 1994;58:283-307.
- Bergman H, Andersson F, Isberg A. Incidence of temporomandibular joint changes after whiplash trauma: a prospective study using MR imaging. *AJR Am J Roentgenol* 1998;171:1237-1243.
- Borchgrevink G, Smevik O, Haave I, Haraldseth O, Nordby A, Lereim I. MRI of cerebrum and cervical columna within two days after whiplash neck sprain injury. *Injury* 1997;28:331-335.
- Bryant D, Norman G, Stratford P, Marx RG, Walter SD, Guyatt G. Patients undergoing knee surgery provided accurate ratings of preoperative quality of life and function 2 weeks after surgery. *J Clin Epidemiol* 2006;59:984-993.
- Carey TS, Garrett J, Jackman A, Sanders L, Kalsbeek W. Reporting of acute low back pain in a telephone interview: identification of potential biases. *Spine* 1995;20:787-790.
- Carroll LJ, Ferrari R, Cassidy JD. Reduced or painful jaw movement after collision-related injuries: a population-based study. *J Am Dent Assoc* 2007;138:86-93.

Carroll LJ, Holm LW, Hogg-Johnsson S, et al. Course and prognostic factors for neck pain in whiplash-associated disorders (WAD): results of the Bone and Joint Decade 2000-2010 Task Force on Neck Pain and Its Associated Disorders. *J Manipulative Physiol Ther* 2009;32:S97-S107.

de Bont LG, Dijkgraaf LC, Stegenga B. Epidemiology and natural progression of articular temporomandibular disorders. *Oral Surg Oral Med Oral Pathol Oral Radiol Endod* 1997;83:72-76.

Dworkin SF, Huggins KH, LeResche L, et al. Epidemiology of signs and symptoms in temporomandibular disorders: clinical signs in cases and controls. *J Am Dent Assoc* 1990;120:273-281.

Dworkin SF, LeResche L. Research diagnostic criteria for temporomandibular disorders: review, criteria, examinations and specifications. *J Craniomandib Disord* 1992;6:301-355.

Fagerlund M, Björnebrink J, Pettersson K, Hildingsson C. MRI in acute phase of whiplash injury. *Eur Radiol* 1995;5:297-301.

Feine JS, Lavigne GJ, Dao TT, Morin C, Lund JP. Memories of chronic pain and perceptions of relief. *Pain* 1998;77:137-141.

Ferrari R, Schrader H, Obelieniene D. Prevalence of temporomandibular disorders associated with whiplash injury in Lithuania. *Oral Surg Oral Med Oral Pathol Oral Radiol Endod* 1999;87:653-657.

Fleiss JL, Cohen J, Everitt BS. Large sample standard errors of kappa and weighted kappa. *Psychol Bull* 1969;72:323-327.

Fleiss JL. Statistical methods for rates and proportions. 2nd ed. New York: Wiley; 1981:218-223.

Fransson P. Recall of pretreatment symptoms among men treated with radiotherapy for prostate cancer. *Acta Oncol* 2005;44:355-361.

Garcia R Jr, Arrington JA. The relationship between cervical whiplash and temporomandibular joint injuries: an MRI study. *Cranio* 1996;14:233-239.

Grönqvist J, Häggman-Henrikson B, Eriksson PO. Impaired jaw function and eating difficulties in whiplash-associated disorders. *Swed Dent J* 2008;32:171-177.

Hans MG, Lieberman J, Goldberg J, Rozencweig G, Bellon E. A comparison of clinical examination, history, and magnetic resonance imaging for identifying orthodontic patients with temporomandibular joint disorders. *Am J Orthod Dentofac Orthop* 1992;101:54-59.

Hansson T, Nilner M. A study of the occurrence of symptoms of diseases of the temporomandibular joint masticatory musculature and related structures. *J Oral Rehabil* 1975;2:313-324.

Harvey AG, Bryant RA. Memory for acute stress disorder symptoms: a two-year prospective study. *J Nerv Ment Dis* 2000;188:602-607.

Heise AP, Laskin DM, Gervin AS. Incidence of temporomandibular joint symptoms following whiplash injury. *J OralMaxillofac Surg* 1992;50:825-828.

Holm L, Cassidy JD, Sjögren Y, Nygren Å. Impairment and work disability due to whiplash injury following traffic collisions. An analysis of insurance material from the Swedish Road Traffic Injury Commission. *Scand J Public Health* 1999;27:116-123.

Howard RP, Benedict JV, Raddin JH, Smith HL. Assessing neck extension-flexion as a basis for temporomandibular joint dysfunction. *J Oral Maxillofac Surg* 1991;49:1210-1213.

Hunter M, Philips C, Rachman S. Memory for pain. *Pain* 1979;6:35-46.

Häggman-Henrikson B, Zafar H, Eriksson PO. Disturbed jaw behavior in whiplash-associated disorders during rhythmic jaw movements. *J Dent Res* 2002;81:747-751.

Häggman-Henrikson B, Österlund C, Eriksson PO. Endurance during chewing in whiplash-associated disorders and TMD. *J Dent Res* 2004;83:946-950.

Isberg A, Hägglund M, Paesani D. The effect of age and gender on the onset of symptomatic temporomandibular joint disk displacement. *Oral Surg Oral Med Oral Pathol Oral Radiol Endod* 1998;85:252-257.

Isberg A, Legrell PE. Facial asymmetry in adults following temporomandibular joint disc displacement with onset during growth. *World J Orthod* 2000;1:164-172.

Johansson AS, Isberg A. The anterosuperior insertion of the temporomandibular joint capsule and condylar mobility in joints with and without internal derangement: a double-contrast arthrotomographic investigation. *J Oral Maxillofac Surg* 1991;49:1142-1148.

Kahn J, Tallents RH, Katzberg RW, Moss ME, Murphy WC. Association between dental occlusal variables and intraarticular temporomandibular joint disorders: horizontal and vertical overlap. *J Prosthet Dent* 1998;79:658-662.

Kasch H, Hjorth T, Svensson P, Nyhuus L, Jensen TS. Temporomandibular disorders after whiplash injury: a controlled, prospective study. *J Orofac Pain* 2002;16:118-128.

Kasch H, Qerama E, Kongsted A, Bendix T, Jensen TS, Bach FW. Clinical assessment of prognostic factors for long-term pain and handicap after whiplash injury: a 1-year prospective study. *Eur J Neurol* 2008;15:1222-1230.

Katzberg RW, Westesson PL, Tallents RH, et al. Temporomandibular joint: MR assessment of rotational and sideways disk displacements. *Radiology* 1988;169:741-748.

Katzberg RW, Westesson P-L, Tallents RH, Drake CM. Anatomic disorders of the temporomandibular joint disc in asymptomatic subjects. *J Oral Maxillofac Surg* 1996;54:147-153.

Kecik D, Kocaderelli I, Saatci I. Condylar disc relationships and vibration energy in asymptomatic class I 9- to 12-year olds. *Angle Orthod* 2005;75:54-62.

Kent G. Memory of dental pain. *Pain* 1985;21:187-194.

Klobas L, Tegelberg A, Axelsson S. Symptoms and signs of temporomandibular disorders in individuals with chronic whiplash-associated disorders. *Swed Dent J* 2004;28:29-36.

Kongsted A, Sorensen JS, Andersen H, Keseler B, Jensen TS, Bendix T. Are early MRI findings correlated with long-lasting symptoms following whiplash injury? A prospective trial with 1-year follow-up. *Eur Spine J* 2008;17:996-1005.

Kronn E. The incidence of TMJ dysfunction in patients who have suffered a cervical whiplash injury following a traffic accident. *J Orofac pain* 1993;7:209-213.

Landis JR, Koch GG. The measurement of observer agreement for categorical data. *Biometrics* 1977;33:159-174.

Larheim TA, Westesson P-L, Sano T. Temporomandibular joint disk displacement: comparison in asymptomatic volunteers and patients. *Radiology* 2001a;218:428-432.

Larheim TA, Katzberg RW, Westesson PL, Tallents RH, Moss ME. MR evidence of temporomandibular joint fluid and condyle marrow alterations: occurrence in asymptomatic volunteers and symptomatic patients. *Int J Oral Maxillofac Surg* 2001b;30:113-117.

Linnman C, Appel L, Fredrikson M, et al. Elevated [¹¹C]-D-deprenyl uptake in chronic whiplash associated disorder suggests persistent musculoskeletal inflammation. *PLoS One* 2011;6:e19182.

Linton SJ, Melin L. The accuracy of remembering chronic pain. *Pain* 1982;13:281-285.

Linton SJ. Memory for chronic pain intensity: correlates of accuracy. *Percept Mot Skills* 1991;72:1091-1095.

Lundh H, Westesson P-L, Kopp S. A three-year follow-up of patients with reciprocal temporomandibular joint clicking. *Oral Surg Oral Med Oral Pathol* 1987;63:530-533.

Masi M, Lederman HM, Yamashita HK, de Arruda Aidar LA. Temporomandibular joint evaluation with magnetic resonance imaging in children with functional unilateral posterior crossbite, treated with rapid maxillary expansion. *Am J Orthod Dentofacial Orthop* 2009;136:207-217.

Milligan ED, Watkins LR. Pathological and protective roles of glia in chronic pain. *Nat Rev Neurosci.* 2009;10:23-36.

Nebbe B, Major PW, Prasad NG. Adolescent female craniofacial morphology associated with advanced bilateral TMJ disc displacement. *Eur J Orthod* 1998;20:701-712.

Nyberg L, Tulving E. Classifying human long-term memory: evidence from converging dissociations. *Eur J Cogn Psychol* 1996;8:163-183.

Paesani D, Salas E, Martinez A, Isberg A. Prevalence of temporomandibular joint disk displacement in infants and young children. *Oral Surg Oral Med Oral Pathol Oral Radiol Endod* 1999;87:15-19.

Pellisé F, Vidal X, Hernández A, Cedraschi C, Bagó J, Villanueva C. Reliability of retrospective clinical data to evaluate the effectiveness of lumbar fusion in chronic low back pain. *Spine* 2005;30:365-368.

Pettersson K, Hildingsson C, Toolanen G, Fagerlund M, Björnebrink J. Disc pathology after whiplash injury. A prospective magnetic resonance imaging and clinical investigation. *Spine* 1997;22:283-287.

Pressman BD, Shellock FG, Schames J, et al. MR imaging of temporomandibular joint abnormalities associated with cervical hyperextension/hyperflexion (whiplash) injuries. *J Magn Reson Imaging* 1992;2:569-574.

Pöllmann L. Sounds produced by the mandibular joint in a sample of healthy workers. *J Orofac Pain* 1993;7:359-361.

Raphael KG, Marbach JJ. When did your pain start?: reliability of self-reported age of onset of facial pain. *Clin J Pain* 1997;13:352-359.

Ribeiro RF, Tallents RH, Katzberg RW, et al. The prevalence of disc displacement in symptomatic and asymptomatic volunteers aged 6 to 25 years. *J Orofacial Pain* 1997;11:37-47.

Ribeiro-Dasilva MC, Peres Line SR, Leme Godoy dos Santos MC, et al. Estrogen receptor-alpha polymorphism and predisposition to TMJ disorder. *J Pain* 2009;10:527-533.

Sato S, Sakamoto M, Kawamura H, Motegi K. Long-term changes in clinical signs and symptoms and disc position and morphology in patients with nonreducing disc displacement in the temporomandibular joint. *J Oral Maxillofac Surg* 1999;57:23-29.

Schwaighofer BW, Tanaka TT, Klein MV, Sartoris DJ, Resnick D. MR imaging of the temporomandibular joint: a cadaver study of the value of coronal images. *AJR Am J Roentgenol* 1990;154:1245-1249.

- Sessle BJ. The neural basis of temporomandibular joint and masticatory muscle pain. *J Orofac Pain* 1999;13:238-245.
- Singer AJ, Kowalska A, Thode HC Jr. Ability of patients to accurately recall the severity of acute painful events. *Acad Emerg Med* 2001;8:292-295.
- Solberg WK, Woo MW, Houston JB. Prevalence of mandibular dysfunction in young adults. *J Am Dent Assoc* 1979;98:25-34.
- Spearing NM, Connelly LB. Is compensation "bad for health"? A systematic meta-review. *Injury* 2011;42:15-24.
- Spitzer WO, Skovron ML, Salmi LR, et al. Scientific monograph of the Quebec Task Force on Whiplash-Associated Disorders: redefining "whiplash" and its management. *Spine* 1995;20 Suppl 8:1-73.
- Sterner Y, Toolanen G, Gerdle B, Hildingsson C. The incidence of whiplash trauma and the effects of different factors on recovery. *J Spinal Disord Tech* 2003;16:195-199.
- Tasaki MM, Westesson PL. Temporomandibular joint: diagnostic accuracy with sagittal and coronal MR imaging. *Radiology* 1993;186:723-729.
- Tasaki MM, Westesson PL, Isberg AM, Ren YF, Tallents RH. Classification and prevalence of temporomandibular joint disk displacement in patients and symptom-free volunteers. *Am J Orthod Dentofacial Orthop* 1996;109:249-262.
- Terry R, Brodie EE, Niven CA. Exploring the phenomenology of memory for pain: is previously experienced acute pain consciously remembered or simply known? *J Pain* 2007;8:467-475.
- Terry RH, Niven CA, Brodie EE, Jones RB, Prowse MA. Memory for pain? A comparison of nonexperiential estimates and patients' reports of the quality and intensity of postoperative pain. *J Pain* 2008;9:342-349.
- Tominaga K, Konoo T, Morimoto Y, Tanaka T, Habu M, Fukuda J. Changes in temporomandibular disc position during growth in young Japanese. *Dentomaxillofac Radiol* 2007;36:397-401.
- Tulving E. Episodic and semantic memory. In: Tulving E, Donaldson W, Bower GH, eds. *Organization of memory*. New York: Academic Press; 1972:381-403.

Tulving E. Episodic memory: from mind to brain. *Annu Rev Psychol* 2002;53:1-25.

Uhrenholt L, Nielsen E, Charles AV, Hauge E, Gregersen M. Imaging occult lesions in the cervical spine facet joints. *Am J Forensic Med Pathol* 2009;30:142-147.

Villa G, Ceruti S, Zanardelli M, et al. Temporomandibular joint inflammation activates glial and immune cells in both the trigeminal ganglia and in the spinal trigeminal nucleus. *Mol Pain* 2010;6:89.

Visscher C, Hofman N, Mes C, Lousberg R, Naeije M. Is temporomandibular pain in chronic whiplash-associated disorders part of a more widespread pain syndrome? *Clin J Pain* 2005;21:353-357.

Weinberg S, Lapointe H. Cervical extension-flexion injury (whiplash) and internal derangement of the temporomandibular joint. *J Oral Maxillofac Surg* 1987;45:653-656.

Westesson PL, Katzberg RW, Tallents RH, Sanchez-Woodworth RE, Svensson SA, Espeland MA. Temporomandibular joint: comparison of MR images with cryosectional anatomy. *Radiology* 1987;164:59-64.

Westesson PL, Katzberg RW, Tallents RH, Sanchez-Woodworth RE, Svensson SA. CT and MR of the temporomandibular joint: comparison with autopsy specimens. *AJR Am J Roentgenol* 1987;148:1165-1171.

Westesson P-L, Lundh H. Arthrographic and clinical characteristics of patients with disk displacement who progressed to closed lock during a 6-month period. *Oral Surg Oral Med Oral Pathol* 1989;67:654-657.

Westling L, Mattiasson A. General joint hypermobility and temporomandibular joint derangement in adolescents. *Ann Rheum Dis* 1992;51:87-90.

Westling L, Holm S, Wallentin I. Temporomandibular joint dysfunction. Connective tissue variations in skin biopsy and mitral valve function. *Oral Surg Oral Med Oral Pathol* 1992;74:709-718.

Zhuo M, Wu G, Wu LJ. Neuronal and microglial mechanisms of neuropathic pain. *Mol Brain* 2011;4:31.