Long-term effects of radiofrequency ablation of the soft palate on snoring.

Elisabeth Hultcrantz, Lena Harder, Helena Loord, Lars-Göran Käll, Kjell Ydreborg, Staffan Wallberg and Eva Svanborg

Elisabeth Hultcrantz, Lena Harder, Helena Loord, Lars-Göran Käll, Kjell Ydreborg, Staffan Wallberg and Eva Svanborg, Long-term effects of radiofrequency ablation of the soft palate on snoring, 2009, European archives of oto-rhino-laryngology: official journal of the European Federation of Oto-Rhino-Laryngological Societies (EUFOS): affiliated with the German Society for Oto-Rhino-Laryngology - Head and Neck Surgery, (267), 1, 137-142.
http://dx.doi.org/10.1007/s00405-009-0979-7

Long-term effects of radiofrequency ablation of the soft palate on snoring

Elisabeth Hultcrantz, Lena Harder, Helena Loord, Lars-Göran Käll, Kjell Ydreborg, Staffan Wallberg and Eva Svanborg

Abstract The objective of the study was to evaluate short- and long-term effects of radiofrequency treatment of the soft palate on snoring. Twenty-nine patients with habitual snoring were studied prospectively and treated up to four times at 4–6 week intervals with an Ellman Surgitrone ®. Electromyography (EMG) of m. palatoglossus was performed in ten patients. Patients and partners evaluated snoring, sleep quality and daytime sleepiness 1 week preoperatively, 6 months and 3–4 years postoperatively. Snoring was reduced postoperatively ($P < 0.0001$). Sleep time increased, daytime sleepiness was reduced, and the partners slept better after 6 months. However, 3–4 years postoperatively only 25% of patients were satisfied. Another 25% had received additional treatment. EMG was normal in 6/10 patients preoperatively. They all continued to snore postoperatively. Four patients had pathological EMGs; three were responders. In conclusion, radiofrequency treatment for snoring may lead to long-term improvement in one out of four cases. Pre-evaluation with EMG may predict the outcome.

Keywords Snoring · RF ablation · Long-term effects Electromyography

Introduction

Snoring is a very common and increasing problem in most societies. In telephone interviews of the general population, it was reported in 40% of UK subjects, 37% of German subjects and 20% of Italians [1]. In Sweden, 25% of females report snoring [2] as does 20% of the male population [3]. A treatment that reduces snoring, causes little discomfort, presents a low risk to the patient and is cost effective for society and therefore, is in great demand.

The majority of patients with obstructive sleep apnea syndrome (OSAS) reports being habitual snorers for years before the onset of daytime fatigue and witnessed apneas. The snoring sound is caused by the vibration of the soft tissue of the upper airway. The long-term use of hand-held vibrating tools may induce local peripheral nerve lesions of the hands [4]. In animal experiments, vibrating a limb will cause peripheral nerve lesions after a couple of weeks [5]. Therefore, it has been hypothesized that snoring-induced vibrations could cause obstructive sleep apnea (OSA) because of motor nerve lesions in the soft palate dilator muscles resulting in partial paresis [6]. This effect on the palatal muscles has been studied in muscle biopsies from habitual snorers and OSAS patients [7] in which signs of peripheral nerve lesions were found in most OSAS cases and, to a lesser extent, in some snorers.

If snoring is an annoyance, is partly, depending on the sound pressure level per se but also on the sensitivity of the listeners [8].The snoring sound is usually emitted by the uvula and soft palate irrespective of oral or nasal breathing. The tonsillar pillars and the walls of the pharynx and hypopharynx are exposed to the suction force (called the Bernoulli effect), which may cause damage. The patient experiences a feeling of soreness in the throat and a lumpy sensation owing to a swollen uvula, especially in the morning. Some patients exhibit an acute edema of the uvula and may be suspected of having an infection, even though the likely cause is “a hard day’s night” with excessive snoring vibrations.

Radiofrequency (RF) ablation of the soft palate heats the tissue around the electrode, disrupting the cells and inducing scarification/fibrosis following the treatment. The amount of heat delivered is related to the content of fluid in the tissue, the closeness to the antenna and the energy level used. A temperature level that does not cause nerve damage is preferable. An Ellman Surgitrone® at 1.7 MHz will, if used according to the manual, heat the tissue to about 70°C, which will not burn the tissue, but will result in the preferred coagulation scarification.

The purpose of the present study was to investigate if treatment of the soft palate with RF waves can reduce snoring both on a short- and long-term basis, and whether or not this effect is occurring in patients that already have signs of peripheral nerve lesions as recorded by electromyography (EMG).

Method

The study was approved by the regional ethics review committee of Linköping University. Inclusion criteria were habitual, socially disruptive snoring, an apnea–hypopnea index (AHI) <10 in a full night sleep respiratory recording, a body-mass index (BMI) <28 and no other known medical disease.

Twenty-six men and four women between 34 and 68 years of age (mean age 48 § 8.12 years) were included and gave an informed consent. Three ENT clinics participated (one university clinic and two clinics at county hospitals), each treating ten patients. The study started at

different times at the three participating clinics because the same RF equipment was used. Because of this, the longterm follow-up was about 4 years for the first clinic and three for the last. The patients answered a questionnaire a week before the first treatment, rating their own snoring habits, sleep quality and general health. This questionnaire (not validated) had been used for many years at the clinic, and data were available in the database for comparisons. They were also requested to keep a diary, made for the study, regarding their sleeping hours, disturbances of sleep, whether they felt refreshed in the mornings and if they had woken up with a sore throat or stuffy nose for a week before each RF treatment. Their partners also maintained their own diary describing their own sleep patterns and how often the patient's snoring each night woke them up. The same questionnaires were repeated 6 months after the last RF treatment. After 3–4 years of treatment, the patients were asked to do a new evaluation of their snoring on a visual analogue scale (VAS) at three different time points: before the first treatment, after the last treatment and at the present time. They were asked whether they were satisfied with their situation ("yes" or "no") with respect to current snoring or if they desired additional contact with a doctor. The patients were also asked if they had been or were presently exposed to other treatments for snoring since the last RF sessions.

EMG

The ten patients treated at the university clinic underwent an EMG examination of the soft palate immediately before the first RF session. A disposable concentric bipolar EMG needle was used (Medtronic Inc., 75 cm length, recording tip 0.64 mm). Needle insertion was made at 2–4 points in the palatoglossal muscles: in the dimple and 1 cm to the left and right of the uvula. The signals were recorded on an EMG machine (Medelec Synergy, Oxford Instruments Inc.). This EMG technique has previously been described [6]. The following Wndings were regarded as pathological:

• Spontaneous activity (fibrillation potentials, positive sharp waves) at rest, indicating an ongoing denervation.
• Polyphasic motor-unit potentials with increased amplitudes (>2 mV) and/or duration, indicating a reinnervation process (i.e., evidence of a previous denervation).
• A reduced interference pattern despite high Wring frequency at maximal voluntary contraction, indicating a loss of motor units typical of peripheral nerve lesions.

For the statistical analysis, the EMG findings were given numerical values. Normal findings were designated 0. The degree of pathology was scored as mild (level 1) if polyphasic or amplitude-increased motor-unit potentials were present. The degree of pathology was scored as moderate (level 2) if both changes in motor-unit potential configuration and reduced amount of voluntary activity were recorded. The degree of pathology was scored as high (level 3) if spontaneous denervation activity was present together with reduced voluntary activity, or if the maximum voluntary activity was reduced to the point where only single potentials could be recorded.

RF treatment

The RF treatments were performed with Ellman Surgitrone at 1.7 MHz (Ellman International 3333 Royal Ave Oceanside, NY 11572 USA) as an office procedure under local anesthesia. The same study protocol was used for all patients. All participating otorhinolaryngologists were instructed to follow the protocol with respect to treatment points, duration and output

level. The first treatment session for each surgeon was performed together with the first author (EH).

During the first session, four locations of the soft palate were treated with two insertion points (Fig. 1) following injection of 1% Lidocain–adrenalin (1 cc) at each treatment point. During the second through fourth sessions, two spots were usually treated. The Surgitrone® was activated after the instrument tip was placed into the palatal muscles. A neutral electrode placed on the patient's neck acted as an antenna. With 20% output (i.e., coagulation mode), the electrode was activated for up to 20 s. During the first treatment session of the first five patients, the rear side of the soft palate was simultaneously observed by fiberoptics to ensure that the electrode placement was not too deep. If the mucous membrane surface turned whitish, the electrode placement was determined to be too superficial and the treatment was ended.

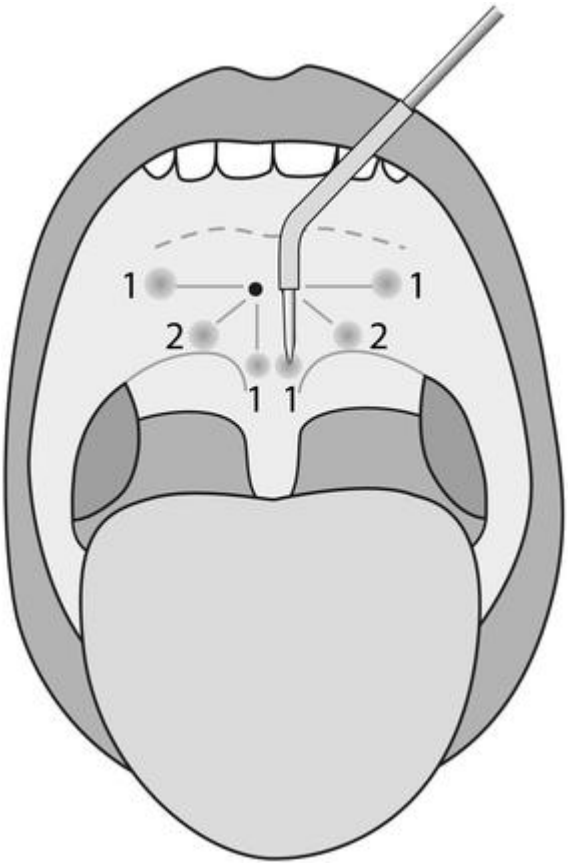

Fig. 1 The treatment field of the soft palate. 1 First treatment session, 2 Second treatment session. The third and fourth sessions were distributed in between 1 and 2 to cover the main part of the palate

Following the procedure, paracetamol (1 g three times/ day) was prescribed to be taken as long as necessary. Patients were told each day to register the experienced maximal pain level on a three-grade scale (no pain, some pain and severe pain). The analgesics were taken until patients were free of pain.

After 2 weeks of treatment, patients were contacted via telephone to evaluate their situation. If no effect on snoring was noticed, a new appointment for treatment was scheduled approximately 6 weeks after the first. The patient was asked to keep a new diary the week before the next treatment. No more than four treatment sessions were planned for this study.

Statistics

Descriptive statistics were used and a Wilcoxon signed rank test was used for dependent variables and for nonparametric variables from the diaries (i.e., snoring and the Epworth sleepiness scale). A χ^2 test was used to compare hours of sleep.

Results

Twenty-nine patients were treated according to the protocol. One patient with type II diabetes got a purulent infection in the palate after the first treatment and was, therefore, excluded. Most patients were treated four times (mean = 3.6).

All 29 patients were both seen at the 6-month follow-up and answered the mailed follow-up inquiry after a mean of 40.3 § 7.7 months (3–4 years).

The post-treatment pain had been almost negligible. Five patients got small ulcers at the insertion sites. These ulcers healed with very little pain within a couple of weeks. The patients followed the prescribed course of paracetamol for the first 3 days and none reported more than a pain level of two on the three-graded scale.

The data for snoring at the three measuring points are shown in Fig. 2. The median snoring VAS score before RF treatment was 8.6, diminishing to 3.6 after 6 months ($P < 0.0001$) and increasing to 5.0 after 3 years. Eleven patients reported a VAS score for snoring ·5 after 3–4 years. Eight of the 29 (28%) patients reported a decrease in snoring to half or less compared with their own baseline ("responders"). These eight responders experienced less daytime sleepiness at the follow-up than before treatment and were more satisfied. Those who were still snoring had a considerably higher score on ESS and were unsatisfied.

The ESS score at the long-term follow-up was 9.8 § 5.2. The results concerning snoring, ESS and "satisfaction with present situation regarding snoring" are shown in Table 1. There was a significant correlation between the degree of snoring as measured by a VAS (0–10), and daytime sleepiness as measured by the ESS scale (0–20; adjusted $R2 = 0.23$, $P = 0.005$; Fig. 3). There was also an inverse relationship between patient "satisfaction" and "degree of snoring" ($R2 = 0.58384694$, $P = 0.000001$, Fig. 4).

Few diaries were completed both by patients and partners for all requested times. Only 10 patients could be evaluated by the comparison of the answers before the first and the fourth treatments and also after 6 months. The number of awakenings each night, as a sign of disturbed sleep for both the patient and the partner, was reduced during the treatment period. The patients and partners reported an increase in sleeping hours as a measure of quality of sleep during the treatment period. However, sleeping time, was back to baseline for the patients after 6 months post-surgery, but the partners were in many cases still sleeping longer (Fig. 5).

Table 1: Snoring before and after RF- treatment and at 4 year follow-up, as well as satisfaction at follow-up measured on VAS

Patient no.	EMG before	Snoring before	Snoring after	Additional treatment	Snoring 4 years	ESS 4 years	Satisfaction 4 years
1		9.3	7.9	0	7.1	3	6
2		7.9	3.6	MAD	8.6	11	0
3		7.9	1.4	0	5.0	3	3
4		7.9	2.1	0	5.7	15	5
5		7.9	2.1	0	1.4	2	8
6		9.3	8.6	0	8.6	3	0
7		9.3	2.1	RFUP	3.6	13	9
8		10.0	10	CPAP	10.0	16	0
9		9.3	5	0	8.6	17	0
10	0	8.6	8.6	0	8.6	12	1
11	0	7.1	7.1	0	7.9	10	1
12	1	7.1	7.1	0	7.1	7	2
13	2	9.3	2.1	0	0.7	4	10
14	0	10.0	8.6	MAD	7.9	11	5
15	0	10.0	6.4	RFUPP	5.7	13	6
16	1	10.0	0.0	0	2.9	9	7
17	0	8.6	1.4[a]	RFUP + MAD,	2.1	3	6
18	2	8.0	3.6	0	4.0	8	6
19	0	8.6	7.1	RFUPP	2.1	10	3
20		5.0	0.7	0	5.0	2	4
21		7.1	3.6	0	6.4	16	2
22		10.0	7.9	0	10.0	11	0
23		8.6	1.4	0	3,6	12	10
24		10.0	2.6	0	9.3	18	6
25		7.9	0.7	0	2.1	6	7
26		7.1	2.1	0	5.7	17	3
27		7.9	1.4	0	5.0	6	5
28		7.9	7.1	0	5.0	8	5
29		8.6	8.6	0	9.3	18	0

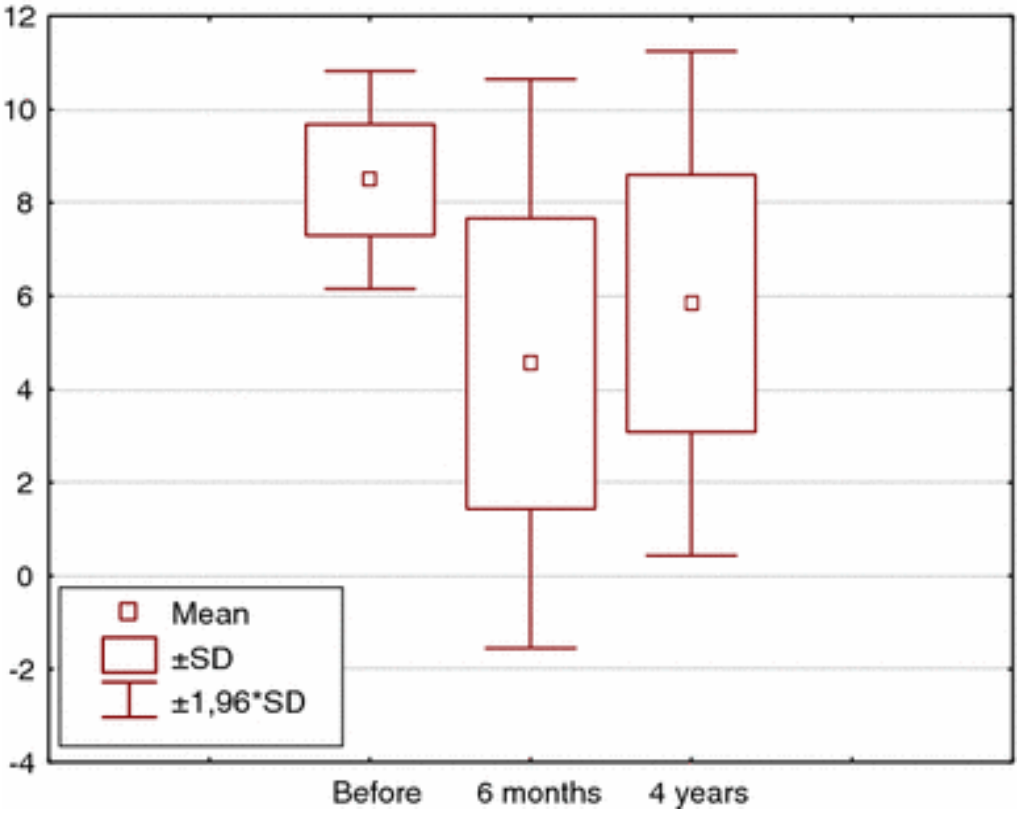

Fig. 2: Snoring before treatment, 6 months after last treatment and after 3–5 years

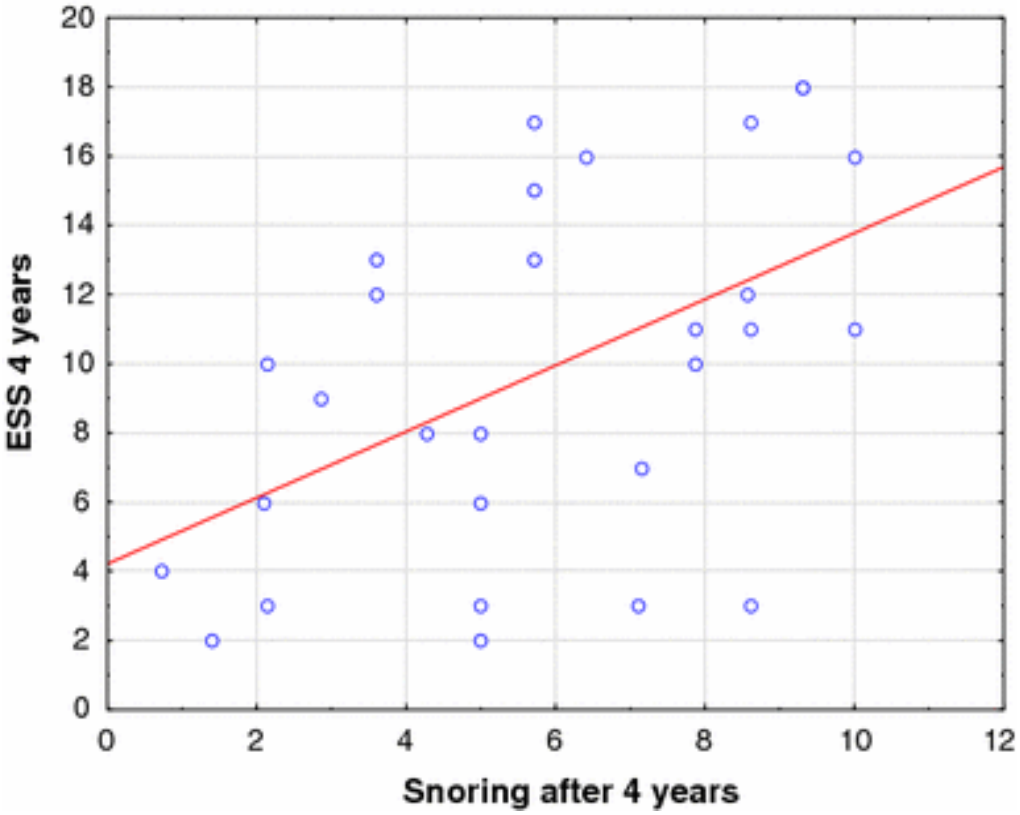

Fig. 3: Comparison between ESS and Snoring (VAS) after 3–4 years

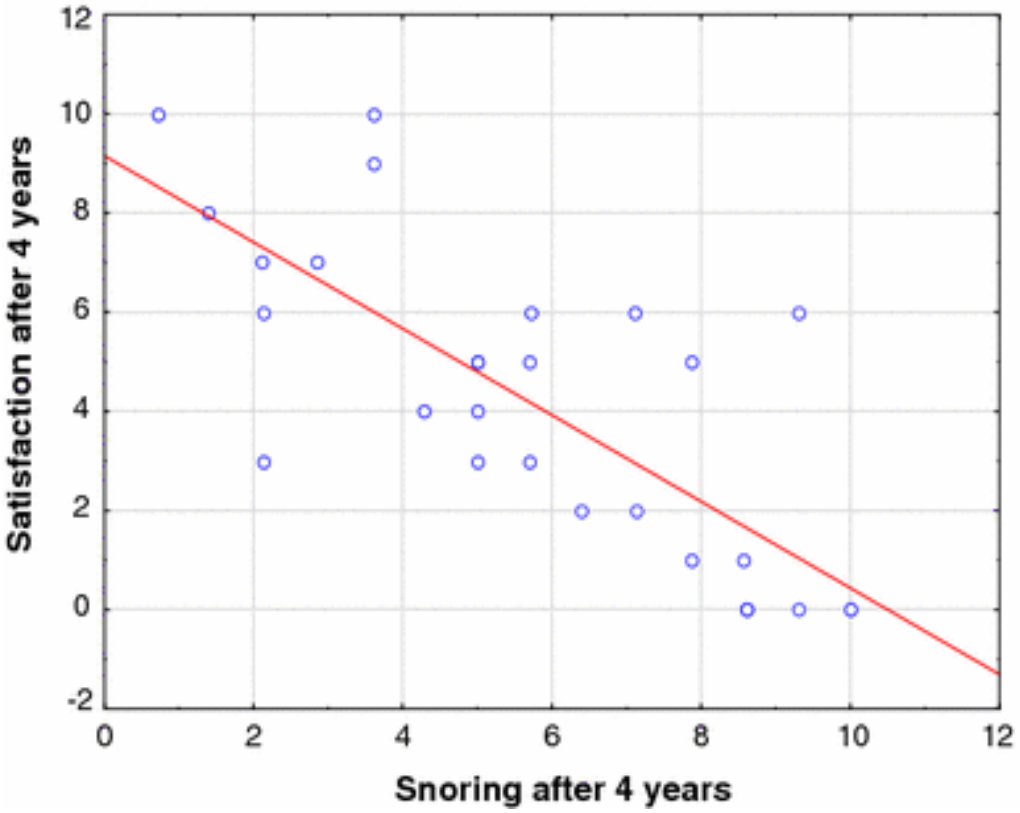

Fig. 4: Comparison between satisfaction and snoring (VAS) after 3–4 years

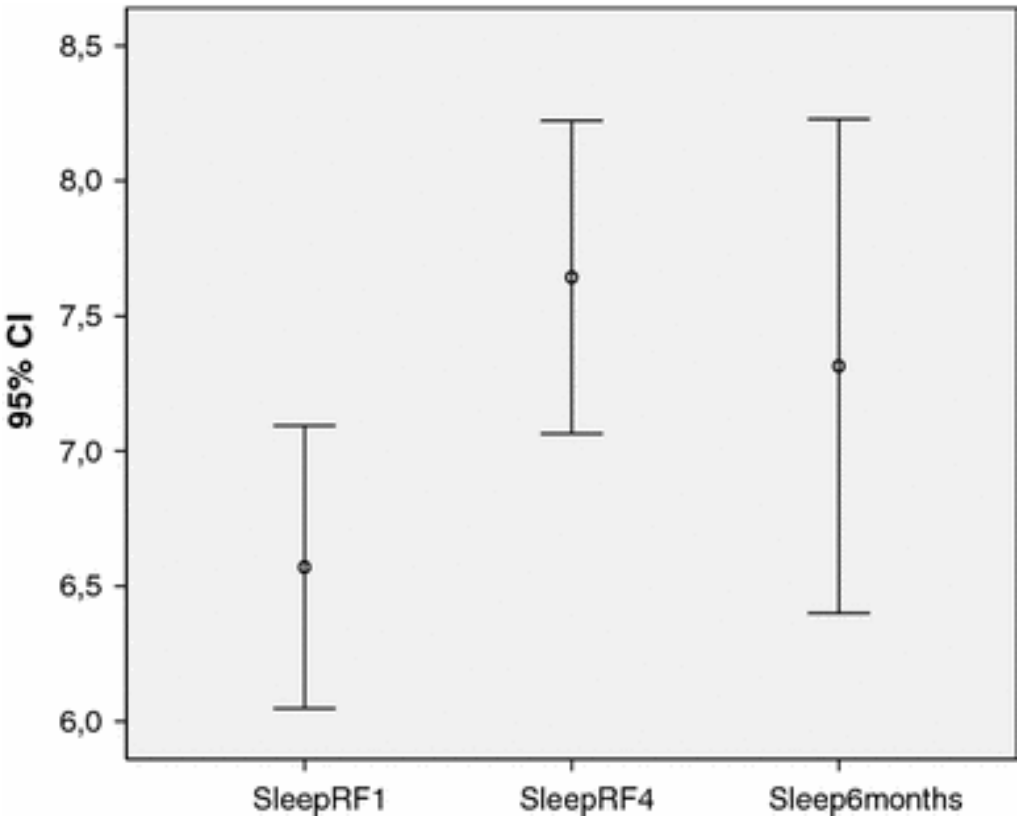

Fig. 5 The partner's estimated hours of sleep before the first and last RF treatment and 6 months after

After the end of the project, eight patients had received additional treatment for snoring such as mandibular advancement devices (n = 4), CPAP (n = 1) or RFUPP (n = 3). The reasons reported for additional treatment were that the patients had not experienced significant improvements following the RF treatment. In two cases, an increased AHI was registered after treatment and resulted in further therapy.

EMG Wndings

The results for the 10 out of 29 patients who were examined with EMG before the Wrst RF treatment are presented in Table 1. Denervation activity was never observed. Five patients had normal EMGs, and three had minor changes in the form of polyphasic and/or amplitude-increased motorunit potentials (indicating a long-standing process with some re-innervation). Two patients had more pronounced changes with decreased voluntary activity, indicating a loss of motor units. The five patients with normal preoperative EMGs all reported continued snoring after treatment, whereas four of the five patients with pathological EMG (two patients with grade 1 changes and two with grade 2 changes) had a significant long-lasting improvement at the 4 years control.

Discussion

This study demonstrates a temporary effect on snoring for most patients after volume reductive/stiffening RF treatment of the soft palate. This is in agreement with the earlier investigations [9–12]. Those studies, however, did not have as long follow-up time as that of the present investigation. One out of four patients in the present study exhibited a more permanent "cure". An interesting question is, thus, whether a positive result could have been predicted before treatment. All five patients with normal EMGs and one with grade 1 (mild) pathology either received additional treatment or were not satisfied after 3–4 years because they snored as much as they did before the first treatment. Of the four out of 10 patients who were regarded as responders after 3–4 years, two had pathological grade 2 EMGs and two had grade 1 EMGs before treatment. In another study where OSA patients, snorers and non-snoring persons were examined with EMG, a successive grading of nerve degeneration was observed with less damage in snorers and more in OSAS patients [13]. This may indicate that for a habitual snorer without neurological vibration damage, the small scar tissue centers created by the RF treatment were not large enough to stop the vibrations of the palate. If nerve damage was already present, however, the delivered stiffening of the scarring process seemed to be sufficient. It is possible that further treatment sessions or more treatment points during each session could have also improved the snoring for patients with normal EMGs.

The RF treatment was uncomplicated and almost pain-free for all "otherwise healthy" patients. The risk for infection has always to be taken into consideration for people with compromised immune systems (e.g. diabetes). Such patients should probably not be recommended for this kind of treatment.

The RF treatment in the present form cannot be regarded as cost-effective, especially with only 28% of the treated patients "cured" after 3–4 years. This has to be compared with other treatments for snoring, such as surgery or mandibular advancement devices (MAD). With respect to surgery, uvulopalatopharyngoplasty (UPP) has approximately 40–80% responders after the same time period [14–16]. With respect to MAD, the compliance after 4 years still is 62% [17]. On the other hand, the treatment with RF causes much less pain than all surgical

modalities [18, 19] and does not require sick leave, which may, therefore, be more economical not only for some patients, but also for society.

A mode to predict positive outcome would be desirable for the RF method. Otherwise, four treatments of 30 patients (a total of 104 sessions) to get 4–5 responders after 3–4 years are considered unreasonable. An EMG examination before the treatment may be such a predictor. The small number of EMG-examined patients in the present study unfortunately makes it impossible to state the predictive value, but it may be an interesting point to evaluate in a future, more extended study.

Conclusion

Intrapalatal treatment with RF for snoring may in one case of four lead to long-term improvement (3–4 years). All cases with normal EMG before treatment were nonresponders.

References

1. Ohayon MM, Guilleminault C, Priest RG, Zulley J, Smirne S (2000) Is sleep-disordered breathing an independent risk factor for hypertension in the general population (13,057 subjects)? J Psychosom Res 48:593–601.
2. Lindberg E, Berne C, Franklin KA, Svensson M, Janson C (2007) Snoring and daytime sleepiness as risk factors for hypertension and diabetes in women—a population-based study. Respir Med 101:1283–1290.
3. Lindberg E, Taube A, Janson C, Gislason T, Svardsudd K, Boman G (1998) A 10-year follow-up of snoring in men. Chest 114:1048–1055.
4. Stromberg T, Dahlin LB, Lundborg G (1998) Vibrotactile sense in the hand-arm vibration syndrome. Scand J Work Environ Health 24:495–502
5. Lundborg G, Dahlin LB, Hansson HA, Kanje M, Necking LE (1990) Vibration exposure and peripheral nerve Wber damage. J Hand Surg Am 15:346–351.
6. Svanborg E (2005) Impact of obstructive apnea syndrome on upper airway respiratory muscles. Respir Physiol Neurobiol 28(147):263–272.
7. Friberg D, Ansved T, Borg K et al (1998) Histological indications of a progressive snorers disease in an upper airway muscle. Am J Respir Crit Care Med 157:586–593
8. Dreher A, Rader T, Patscheider M, Klemens C, Schmidt M, Baker F, de la Chaux R (2009) The annoyance of snoring. Eur Arch Otorhinolaryngol 266(2):293–296.
9. Stuck BA, Sauter A, Hormann K, Verse T, Maurer JT (2005) Radiofrequency surgery of the soft palate in the treatment of snoring: a placebo-controlled trial. Sleep 28:847–850
10. Li KK, Powell NB, Riley RW, Troell RJ, Guilleminault C (2000) Radiofrequency volumetric reduction of the palate: an extended follow-up study. Otolaryngol Head Neck Surg 122:410–414.
11. Farrar J, Ryan J, Oliver E, Gillespie MB (2008) Radiofrequency ablation for the treatment of obstructive sleep apnea: a meta-analysis. Laryngoscope 118(10):1878–1883.
12. Uloza V, Balsevibius T, Sakalauskas R, Miliauskas S, Zemaitienñ N (2008) Changes in emotional state of snoring and obstructive sleep apnea patients following radiofrequency tissue ablation. Eur Arch Otorhinolaryngol [Epub ahead of print]
13. Svanborg E, Hagander L, Haraldsson P-O, Harder L, Hultcrantz E (2006) Electromyographic Wndings in the upper airway of patients with obstructive sleep apnea and snoring. J Sleep Res 15(Suppl 1):112

14. Janson C, Gislason T, Bengtsson H et al (1997) Long-term follow up of patients with obstructive sleep apnea syndrome (OSAS) treated with uvulopalatopharyngoplasty (UPPP). Arch Otolaryngol Head Neck Surg 123:157–162
15. Hultcrantz E, Johansson K, Bengtson H (1999) 5–7 year follow-up after UPP in local anesthesia. J Laryngol Otol 113:542–547.
16. Friberg D, Carlsson-Nordlander B, Larsson H, Svanborg E (1995) UPPP for habitual snoring: a 5-year follow-up with respiratory sleep recordings. Laryngoscope 105:519–522.
17. Walker-Engström M-L, Tegelberg A Wilhelmsson B, Ringqvist I (2002) 4-year follow-up of treatment with dental appliance or uvulopalatopharyngoplasty in patients with obstructive sleep apnea: a randomized study. Chest 121:739–746.
18. Troell RJ, Powell NB, Riley RW, Li KK, Guilleminault C (2000) Comparison of postoperative pain between laser-assisted uvulopalatoplasty, uvulopalatopharyngoplasty, and radiofrequency volumetric tissue reduction of the palate. Otolaryngol Head Neck Surg 122:402–409
19. Lim DJ, Kang SH, Kim BH, Kim HG (2007) Treatment of primary snoring using radiofrequency-assisted uvulopalatoplasty. Eur Arch Otorhinolaryngol 264(7):761–767