

OPEN

Intracranial Pressure Dynamics and Cerebral Vasomotor Reactivity in Coronavirus Disease 2019 Patient With Acute Encephalitis

Teodor Svedung Wettervik, MD¹; Eva Kumlien, MD, PhD²; Elham Rostami, MD, PhD¹; Timothy Howells, PhD¹; Magnus von Seth, MD, PhD³; Vilma Velickaite, MD⁴; Anders Lewén, MD, PhD¹; Per Enblad, MD, PhD¹

Objectives: We describe the intracranial pressure dynamics and cerebral vasomotor reactivity in a coronavirus disease 2019 patient with acute encephalitis treated with cerebrospinal fluid drainage and therapeutic plasma exchange.

Data Sources: Coronavirus disease ICU, Uppsala University Hospital, Sweden.

Study Selection: Case report.

Data Extraction: Radiology, intracranial pressure, intracranial compliance (correlation between intracranial pressure amplitude and mean intracranial pressure), cerebral vasomotor reactivity (pressure reactivity index), arterial blood pressure, cerebrospinal fluid chemistry, and treatment.

Data Synthesis: None.

Conclusions: This is the first reported case of intracranial pressure monitoring in a patient with acute encephalitis following coronavirus disease 2019. Intracranial pressure data exhibited a high incidence of plateau waves with intracranial pressure insults above 40 mm Hg that required cerebrospinal fluid drainage. Intracranial compliance was low, and pressure reactivity was intact. It is probable that the combination of low intracranial compliance and

intact pressure autoregulation explain the high degree of plateau intracranial pressure waves and intracranial pressure variability. This case illustrates that it could be of value to consider intracranial pressure monitoring in selected coronavirus disease 2019 patients with suspicion of increased intracranial pressure to be able to confirm and treat intracranial hypertension if needed. In this patient, therapeutic plasma exchange was safe and efficacious as the level of neuroinflammation decreased and the patient regained consciousness.

Key Words: acute encephalitis; coronavirus disease 2019; intracranial compliance; intracranial pressure; pressure autoregulation; therapeutic plasma exchange

Since the spread of the severe acute respiratory syndrome coronavirus 2 (SARS-CoV-2) and the corresponding coronavirus disease 2019 (COVID-19) in Wuhan, there have been more than 14,730,000 cases worldwide of which 611,000 have died (1). The clinical presentation is usually dominated by respiratory symptoms. In severe cases, a systemic hyperinflammatory state, followed by multiple system organ failure, is seen (2). Neurologic symptoms such as anosmia are common, but severe neurologic manifestations are rarely reported (3). However, a few case reports have described some severe neurologic cases following COVID-19, such as diffuse brain edema (4), acute necrotizing encephalopathy (ANE) (5), acute disseminated encephalomyelitis (ADEM) (6), and acute stroke (7).

This is to our knowledge the first case report of a patient with COVID-19 with encephalitis receiving neurointensive care with intracranial pressure (ICP) monitoring.

CASE PRESENTATION

A previously healthy female patient in her forties sought medical care at a primary hospital in Sweden due to respiratory symptoms. Reverse transcription polymerase chain reaction

¹Department of Neuroscience, Section of Neurosurgery, Uppsala University, Uppsala, Sweden.

²Department of Neuroscience, Section of Neurology, Uppsala University, Uppsala, Sweden.

³Department of Surgical Sciences, Section of Anaesthesia and intensive care, Uppsala University, Uppsala, Sweden.

⁴Department of Surgical Sciences, Section of Radiology, Uppsala University, Uppsala, Sweden.

Copyright © 2020 The Authors. Published by Wolters Kluwer Health, Inc. on behalf of the Society of Critical Care Medicine. This is an open-access article distributed under the terms of the Creative Commons Attribution-Non Commercial-No Derivatives License 4.0 (CCBY-NC-ND), where it is permissible to download and share the work provided it is properly cited. The work cannot be changed in any way or used commercially without permission from the journal.

Crit Care Expl 2020; 2:e0197

DOI: 10.1097/CCE.0000000000000197

for SARS-CoV-2 was positive, and a CT of her thorax showed COVID-19-associated pulmonary findings. Four days from onset of symptoms, her respiratory status deteriorated, and she was intubated and mechanically ventilated. No neurologic deficits were noted before intubation. Her respiratory status gradually improved, and a wake-up test was performed after 5 days in respirator. She showed no reaction to pain stimuli (Glasgow Coma Scale Motor [GCS M] score 1) and had normal pupillary size with sluggish reaction to light. CT and MRI of the brain showed white matter brain edema with associated microhemorrhages with involvement of basal ganglia, in line with acute hemorrhagic leukoencephalitis (AHLE) (Fig. 1). The basal cisterns were open, but the convexity sulci were slightly compressed. On day 10, the patient was transferred to a dedicated COVID-19 ICU at our university hospital.

At admission to the ICU, she showed no reaction to central pain stimulation and no withdrawal of arms to peripheral pain stimulation. The pupillary status was unchanged. Since she was unconscious and had brain edema, we inserted an external ventricular drain (EVD) (VentrEX; Neuromedex, Hamburg, Germany) to monitor ICP and to analyze the cerebrospinal fluid (CSF). Arterial blood pressure (ABP) was also measured invasively in the radial artery at heart level. The sampling frequency for the ICP and ABP waveform data was 100 Hz, and the analyses described below were performed in the Odin Browser (8). ICP was initially low during the first hours after EVD insertion, but some B-waves (ICP waves with a low frequency and small amplitude) occurred. A few hours later, plateau waves with ICP

above 40 mm Hg developed that required the first opening of the EVD for CSF drainage with a corresponding normalization of ICP (Fig. 2A). The first day, there were in total seven episodes of a sudden rise in ICP greater than 30 mm Hg (three with ICP > 40 mm Hg), with corresponding reductions of cerebral perfusion pressure less than 60 mm Hg. The plateau waves were treated with temporary opening of the EVD, and during 14 hours the first day, the EVD was kept open against a pressure gradient of 20 mm Hg. The mean ICP for the first day was low but intracranial compliance (r ; the correlation between ICP amplitude and mean ICP [RAP]) (9) was low (high RAP), indicating an exhausted capability to tolerate increased intracranial volume without a rise in ICP (Fig. 2B). Cerebral blood flow pressure autoregulation was intact according to the pressure reactivity index (PRx, correlation between ABP and ICP; negative values indicate intact autoregulation) (10).

The CSF analysis after EVD insertion showed an increase in erythrocytes ($10,000 \times 10^6/L$) and leukocytes ($21 \times 10^6/L$ polynuclear and $25 \times 10^6/L$ mononuclear), normal glucose (4.8 mM), and albumin (239 mg/L, normal 90–330). The repeated CSF cell count showed slightly lower erythrocytes ($555 \times 10^6/L$) and leukocytes ($6 \times 10^6/L$ polynuclear and $1 \times 10^6/L$ mononuclear) 2 days later. Further CSF analyses were negative for bacteria (culture), neurotropic viruses (enterovirus, herpes simplex I and II, and varicella-zoster virus), and SARS-CoV-2. There were no neuronal antibodies in CSF, while the electrophoresis showed identical bands of immunoglobulin G (IgG) in plasma and CSF, indicating passive transport of IgG from plasma to CSF, but no unique bands in CSF. Interleukin (IL)-6 levels in CSF and plasma were increased to 485 and 29 ng/L, respectively. Electroencephalographic analyses showed a pronounced, generalized slowing over both hemispheres, but no electrographic epileptic activity.

The patient was sedated with propofol infusion, P_{CO_2} was kept within 4.5–6.0 kPa, and the targeted arterial oxygen level was above 12 kPa. She was treated with therapeutic plasma exchange (TPE) for 5 days after the plasma and CSF analyses mentioned above had been performed. The need for temporary opening of the EVD to control ICP decreased gradually. Along with the ICP decrease, RAP gradually improved while the pressure reactivity remained intact (Fig. 2). The total amount of CSF drained from the EVD decreased from 91 mL the first day to only 4 mL 5 days after EVD insertment, and it was removed after 6 days. The level of neuroinflammation decreased, as indicated by the gradual reduction

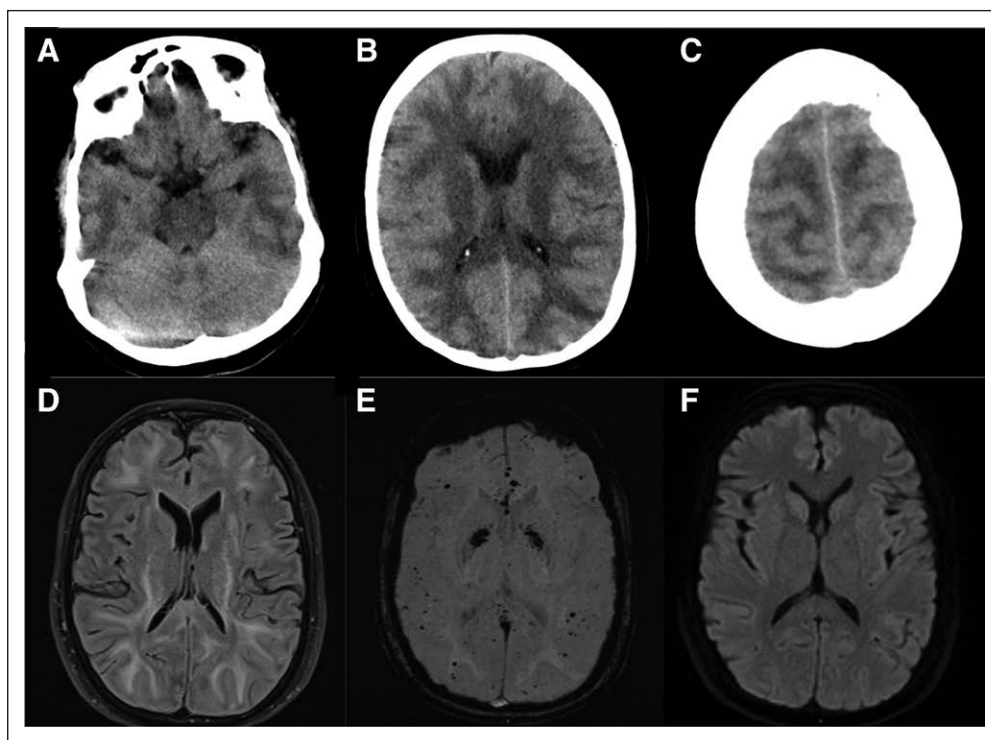


Figure 1. CT and MRI of the brain. The CT scans (A–C) showed white matter brain edema with compressed convexity sulci. The MRI scans (D–F) showed increased white matter intensity on flair images (D), microhemorrhages with involvement of basal ganglia on SWI (E), and no signal changes on diffusion-weighted imaging (DWI) (F). The findings resembled acute hemorrhagic leukoencephalitis. SWI = susceptibility-weighted imaging.

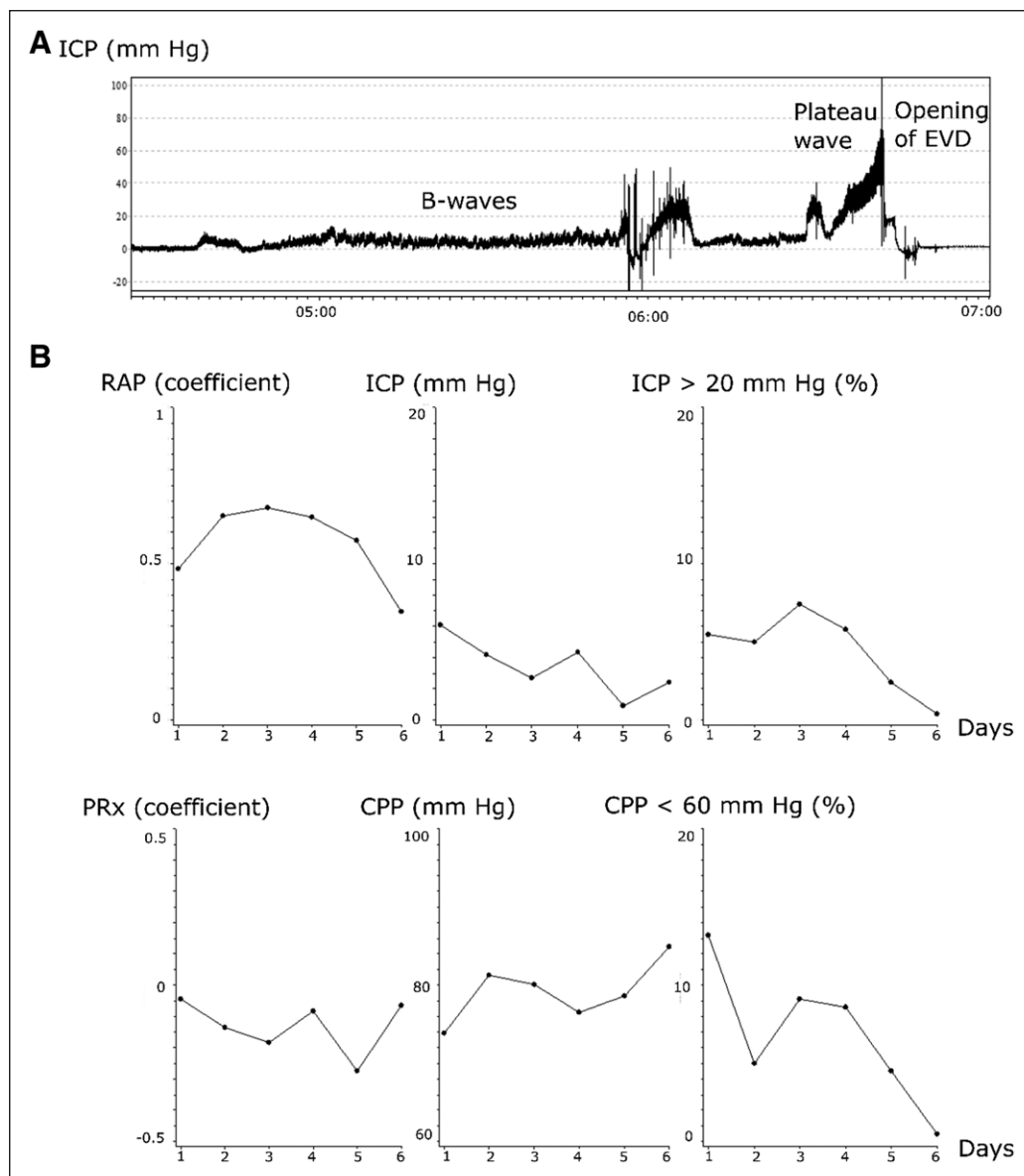


Figure 2. Intracranial pressure (ICP) dynamics the first 6 d after admission. The external ventricular drain (EVD) was inserted around midnight the first day, and ICP was initially low. B-waves (low-frequency ICP waves of smaller amplitude) were first present and later developed into plateau waves with ICP above 40 mm Hg, which led to the first intermittent opening of the EVD for cerebrospinal fluid drainage (**A**). **B**, Mean daily values of the correlation between ICP amplitude and mean ICP (RAP), ICP, pressure reactivity index (PRx), and cerebral perfusion pressure (CPP). The good monitoring time of ICP above 20 mm Hg and CPP below 60 mm Hg are also demonstrated. The figure indicates that intracranial compliance was low (high RAP), whereas pressure autoregulation was intact (PRx below 0).

in CSF IL-6 following TPE (**Fig. 3**). Control CT showed a minor hemorrhage along the EVD channel and in the right ventricle. The patient experienced a significant clinical improvement in the level of consciousness and was extubated after 4 days of treatment with TPE. She could be discharged to the ICU at the primary hospital after 8 days at the university hospital in Uppsala. Her neurologic status had improved to GCS M 6. She was generally fatigued, but with no focal neurologic deficits. A MRI of the brain at discharge showed that the white matter brain edema and microhemorrhages were unchanged. There were no pathologic findings in the spine. She gave her informed consent for this case report at 1-month follow-up.

DISCUSSION

This is the first report of a patient with ICP monitoring due to COVID-19-associated encephalitis. The MRI showed a picture resembling AHLE with compressed sulci. The ICP data exhibited a high frequency of intracranial hypertension and support the need for ICP monitoring and treatment in selected COVID-19 cases with severe neurologic manifestations and radiological signs of increased ICP.

To our knowledge, there is no previous case reported with COVID-19-associated coma and ICP monitoring. As our patient presented with a reduced level of consciousness and white matter brain edema with compressed convexity sulci, we could not exclude intracranial hypertension, and we inserted an EVD to monitor ICP and analyze CSF for differential diagnoses. The ICP data showed a high frequency of plateau waves with ICP insults above 40 mm Hg that required CSF drainage. Intracranial compliance was low, and pressure reactivity was intact. The combination of low intracranial compliance and intact pressure autoregulation could explain the high degree of plateau ICP waves. When the intracranial compliance is low, reactive cerebral vessels lead to rapid changes in cerebral blood volume with great impact on ICP (11, 12). The high frequency of severe ICP insults in our case highlights the potential importance of ICP monitoring

to detect and treat intracranial hypertension in selected patients to avoid secondary brain injuries. The EVD was open for some hours on the first day after insertion, and there are concerns that the physiologic data behind RAP and PRx were then corrupted. However, at least PRx seems valid when the EVD is open in previous studies (13), but less is known about RAP, and this measure should therefore be analyzed with caution on day 1.

Furthermore, previously, one COVID-19-related case of ANE involving both thalami (5) and one patient with ADEM (6) have been described, but to our knowledge, no known case of AHLE has been reported. Our patient demonstrated a reduced level of consciousness and structural brain damage, including diffuse white matter brain

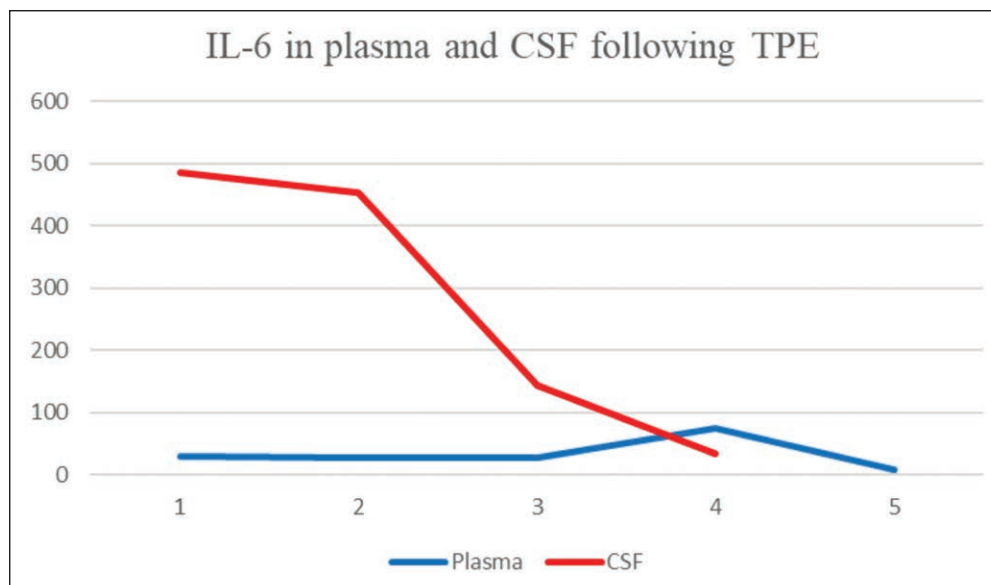


Figure 3. Temporal dynamics of interleukin-6 (IL-6) in plasma and cerebrospinal fluid (CSF). IL-6 (ng/L) in CSF reduced from day 1 (before treatment) to day 4 following treatment with therapeutic plasma exchange (TPE).

edema with microhemorrhages. The CSF analysis showed slight leukocytosis, increased CSF IL-6, and was negative for SARS-CoV-2 and other infectious agents. These findings might indicate the diagnosis AHLE (14). AHLE is uncommon overall, and there is only a limited number of previously reported cases (15). AHLE typically occurs following infections and is hypothesized to be an autoimmune disease due to cross-reactivity of human antibodies between infectious agents and human myelin. The fatality rate is high and intracranial hypertension is common and detrimental (15, 16). The need for ICP monitoring and management might therefore be particularly important to avoid secondary brain injuries. In addition, steroids, IV immunoglobulins (IVIGs), and TPE might improve outcome in AHLE (15). In this case, we were afraid to worsen the COVID-19-infection with high-dose steroids (based on the evidence at the time) (17) and further increase the risk of thromboembolism with IVIG (18). We therefore chose TPE treatment for 5 days. The treatment was safe and efficacious as the patient showed clinical and biochemical improvements, while no adverse effects were noted.

CONCLUSIONS

This is the first reported case of a COVID-19-associated coma with ICP monitoring. We found that intracranial hypertension was initially common and required intermittent CSF drainage. This highlights that ICP monitoring is important to consider in selected COVID-19 patients to detect and treat eventual intracranial hypertension. The condition in this patient was characterized by a reduction in consciousness with radiological findings of white matter brain edema and microhemorrhages, with increased IL-6 in CSF, which was in line with the diagnosis AHLE. TPE was safe and associated with clinical and biochemical improvement.

The authors have disclosed that they do not have any potential conflicts of interest.

For information regarding this article, E-mail: teodor.svedung-wettervik@neuro.uu.se

This work was performed at Uppsala University Hospital, Sweden.

REFERENCES

1. World Health Organization: Coronavirus Disease (COVID-19) Pandemic. 2020. World Health Organization. Available at: <https://www.who.int/emergencies/diseases/novel-coronavirus-2019>. Accessed July 22, 2020
2. Merad M, Martin JC: Pathological inflammation in patients with COVID-19: A key role for monocytes and macrophages. *Nat Rev Immunol* 2020; 20:355–362
3. Needham EJ, Chou SH, Coles AJ, et al: Neurological Implications of COVID-19 Infections. *Neurocrit Care* 2020; 32:667–671
4. Xu Z, Shi L, Wang Y, et al: Pathological findings of COVID-19 associated with acute respiratory distress syndrome. *Lancet Respir Med* 2020; 8:420–422
5. Poyiadji N, Shahin G, Noujaim D, et al: COVID-19-associated acute hemorrhagic necrotizing encephalopathy: CT and MRI features. *Radiology* 2020; 296:E119–E120
6. Zhang T, Rodricks MB, Hirsh E: COVID-19-associated acute disseminated encephalomyelitis: A case report. *medRxiv* 2020.04.16.20068148
7. Helms J, Kremer S, Merdji H, et al: Neurologic features in severe SARS-CoV-2 infection. *N Engl J Med* 2020; 382:2268–2270
8. Howells T, Elf K, Jones PA, et al: Pressure reactivity as a guide in the treatment of cerebral perfusion pressure in patients with brain trauma. *J Neurosurg* 2005; 102:311–317
9. Czosnyka M, Guazzo E, Whitehouse M, et al: Significance of intracranial pressure waveform analysis after head injury. *Acta Neurochir (Wien)* 1996; 138:531–541; discussion 541–542
10. Czosnyka M, Smielewski P, Kirkpatrick P, et al: Continuous assessment of the cerebral vasomotor reactivity in head injury. *Neurosurgery* 1997; 41:11–17; discussion 17–19
11. Svedung Wettervik T, Howells T, et al: Intracranial pressure variability: Relation to clinical outcome, intracranial pressure-volume index, cerebrovascular reactivity and blood pressure variability. *J Clin Monit Comput* 2020; 34:733–741
12. Czosnyka M, Smielewski P, Piechnik S, et al: Hemodynamic characterization of intracranial pressure plateau waves in head-injury patients. *J Neurosurg* 1999; 91:11–19
13. Howells T, Johnson U, McKelvey T, et al: The effects of ventricular drainage on the intracranial pressure signal and the pressure reactivity index. *J Clin Monit Comput* 2017; 31:469–478
14. Kuperan S, Ostrow P, Landi MK, et al: Acute hemorrhagic leukoencephalitis vs ADEM: FLAIR MRI and neuropathology findings. *Neurology* 2003; 60:721–722
15. Ryan LJ, Bowman R, Zantek ND, et al: Use of therapeutic plasma exchange in the management of acute hemorrhagic leukoencephalitis: A case report and review of the literature. *Transfusion* 2007; 47:981–986
16. Barnett GH, Ropper AH, Romeo J: Intracranial pressure and outcome in adult encephalitis. *J Neurosurg* 1988; 68:585–588
17. Russell CD, Millar JE, Baillie JK: Clinical evidence does not support corticosteroid treatment for 2019-nCoV lung injury. *Lancet* 2020; 395:473–475
18. Stiehm ER: Adverse effects of human immunoglobulin therapy. *Transfus Med Rev* 2013; 27:171–178