

**Impairment of intra-oral sensation,
discrimination ability, and swallowing function
following radiotherapy and surgery
for oral and pharyngeal cancer**

Ingrid Bodin



Department of Odontology, Oral and Maxillofacial Radiology,
Umeå University, Umeå, Sweden

2004

Department of Odontology, Oral and Maxillofacial Radiology,
Umeå University,
SE-901 87 Umeå, Sweden

Copyright © by Ingrid Bodin
ISBN 91-7305-651-0
ISSN 0345-7532-85

Printed in Sweden
Larsson & Co:s Tryckeri AB
Umeå 2004

CONTENTS

PREFACE.....5

ABSTRACT.....6

DEFINITIONS.....7

INTRODUCTION.....9

BACKGROUND TO THIS PROJECT.....19

AIMS.....20

MATERIAL21

METHODS.....22

RESULTS.....31

DISCUSSION.....34

CONCLUSIONS.....39

REFERENCES.....40

PREFACE

This thesis is based on the following studies, which will be referred to in the text by their roman numerals:

- I Bodin IKH, Lind MG and Arnander C. Free radial forearm flap reconstruction in surgery of the oral cavity and pharynx: surgical complications, impairment of speech and swallowing. Clin Otolaryngol 1994; 19: 28-34.
- II Bodin I, Lind MG, Henningsson G and Isberg A. Deterioration of intraoral hole size identification after treatment of oral and pharyngeal cancer. Acta Otolaryngol 1999; 119: 609-616.
- III Bodin I, Lind MG, Henningsson G and Isberg A. Deterioration of intraoral recognition of shapes after treatment of oral and pharyngeal cancer. Otolaryngol Head Neck Surg 2000; 122: 584-589.
- IV Bodin I, Levring Jäghagen E and Isberg A. Intra-oral sensation before and after radiotherapy and surgery for oral and pharyngeal cancer. Accepted for publication in Head and Neck.
- V Levring Jäghagen E, Bodin I and Isberg A. Pharyngeal swallowing dysfunction following treatment for oral and pharyngeal cancer - association with diminished intra-oral sensation and discrimination ability. In manuscript.

ABSTRACT

Oral and pharyngeal cancer is commonly treated with a combination of radiotherapy and surgery. It is a clinical knowledge that patients often experience severe swallowing disorders following treatment. Since surgical sequelae are instantaneous and obvious, little attention has been paid to other concurrent effects of the treatment. To shed light on this subject, the aim of this thesis was twofold (i) to make a retrospective inventory of the sequelae following treatment and (ii) to perform a prospective, inceptive examination at diagnosis, and to follow-up after radiotherapy, six and 12 months after surgery.

The files of ninety-nine patients revealed that following treatment one-third had to use gastric fistulas and more than nine of ten patients had restricted swallowing capacity. Every second patient could only swallow puréed or liquid food.

Adequate intraoral sensation and discrimination ability is essential for bolus preparation and bolus control, for appropriate elicitation of the swallowing reflex and, hence, for the oral phase of swallowing. At the inceptive examination, the prospective part of the study demonstrated that intra-oral discrimination ability in patients was equal to that in healthy reference individuals but was impaired six months after treatment, and there was no significant improvement after 12 months. It had been expected that the patient's healthy, non-tumor side would compensate but it did not. An explanation was found when it was revealed that radiotherapy induced a delayed decline in intra-oral sensation. Sensory decline was not demonstrated within a month after radiotherapy but was manifest six months later. Since the radiotherapy field includes the neck, because of the risk for metastasis, it is highly plausible that pharyngeal sensation declines in a manner corresponding to that found intraorally when the healthy side is irradiated. In accord with this presumption, pharyngeal swallowing function deteriorated in patients with oral tumors. Cineradiographic evaluation of oral and pharyngeal swallowing function disclosed a significant association between the degree of swallowing dysfunction and the degree of sensory decline and with the degree of impairment of shape recognition.

Conclusions: Delayed intra-oral sensory decline, found to be induced by radiotherapy, can be expected to appear in the entire radiation field, including the oral cavity and the pharynx, with adverse effect on swallowing. Testing intraoral sensation close to the last radiotherapy session is not advisable, because sensory decline does not develop immediately after radiotherapy but manifests after six months. Spontaneous sensory rehabilitation cannot be expected after six months. The significant association between degree of swallowing dysfunction and degree of intraoral sensory decline and impaired discrimination ability must be considered in the quest for functional rehabilitation of patients treated for oral or pharyngeal cancer.

Keywords: Oral and pharyngeal cancer, radiotherapy, surgery, intra-oral sensation, sensibility, intra-oral discrimination, deglutition disorders, dysphagia, swallowing, function, dysfunction, radiography, cineradiography, follow-up.

DEFINITIONS

Aspiration: The act of inhaling. Radiographic definition: When the bolus penetrates below the vocal cords.

Bolus: A rounded mass of food being masticated and swallowed. *Alimentary bolus*: The mass of food in the pharynx or esophagus comprising one swallow; in this thesis referred to as bolus. Radiographically: A single dose of contrast medium, given all at once.

Cineradiography: The making of a motion picture record of the successive radiographic images appearing on a fluoroscopic screen. The images are recorded by a cine camera and stored on film.

Dysphagia: Difficulty swallowing. In this study the term is restricted to include symptoms reported by the patient.

Gastrostomia: A permanent feeding tube percutaneously installed in the ventricle providing artificial alimentation.

Gray (Gy): 1Gy = 1 Joule/kg. Absorbed dose.

Penetration: When the bolus penetrates into the laryngeal vestibule but not below the vocal cords.

Swallowing dysfunction is objectively evaluated and can be symptomatic or asymptomatic, *i.e.* a patient with swallowing dysfunction can suffer from dysphagia or be unaware of the dysfunction. In this study the term implies radiographically verified objective signs with or without symptoms of dysphagia.

Videoradiography: Same as cineradiography but the images are recorded by a Vidicon camera and stored on videotape.

INTRODUCTION

The results of this thesis address specialists of different disciplines in medicine, odontology, speech pathology, speech therapy, and dietitians involved in the treatment of oral and pharyngeal cancer and following rehabilitation. An overview of the anatomy and function of the oral cavity and pharynx is therefore given as background.

ANATOMY

The oral cavity (Fig. 1)

The entrance to the digestive canal is through the lips. The lips and the tip of the tongue are among the most sensitive parts of the human body. These delicate structures protect the digestive canal from swallowing harmful agents. The upper extent of the oral cavity is the hard palate, and the lower is the mylohyoid muscle, strained in the mandibular bow, on which the tongue is based. To the sides the oral cavity is bounded by the cheeks. From back to front, the tongue fills the entire oral cavity. In the rear the oral cavity is connected to the oropharynx via the pharyngeal pillars. The soft palate constitutes the demarcation to the nasopharynx (Fig. 2). The teeth are important for effective mastication. The tongue is the transporter of the bolus to the area of the pharyngeal pillars where the swallow is initiated. The surface of the oral cavity consists of mucous membrane, covered by squamous cell epithelium, which, in contrast to skin, tolerates humidity. Three pairs of large and numerous small salivary glands secrete saliva into the oral cavity, to blend and lubricate the bolus during mastication, in order to facilitate the swallow (Petrén, Carlsöö 1983, Sobotta 1994, Gaziano 2002).

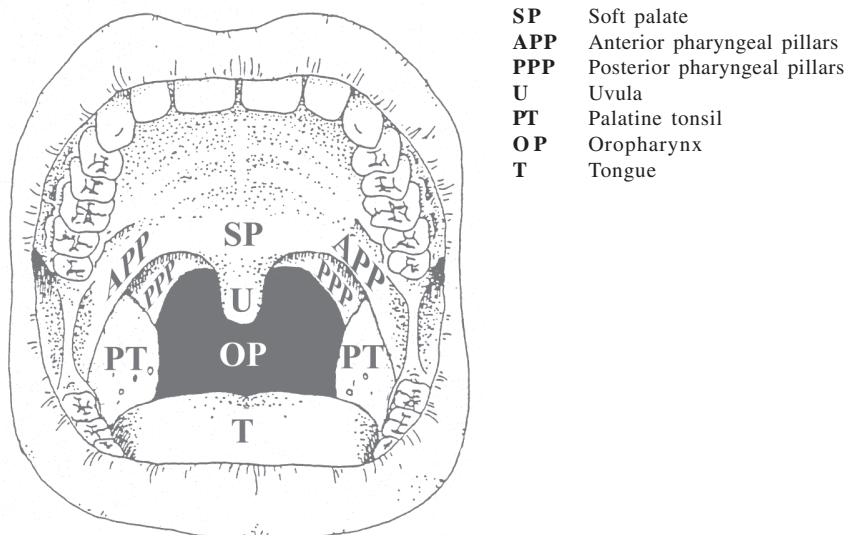


Figure 1.
The oral cavity.

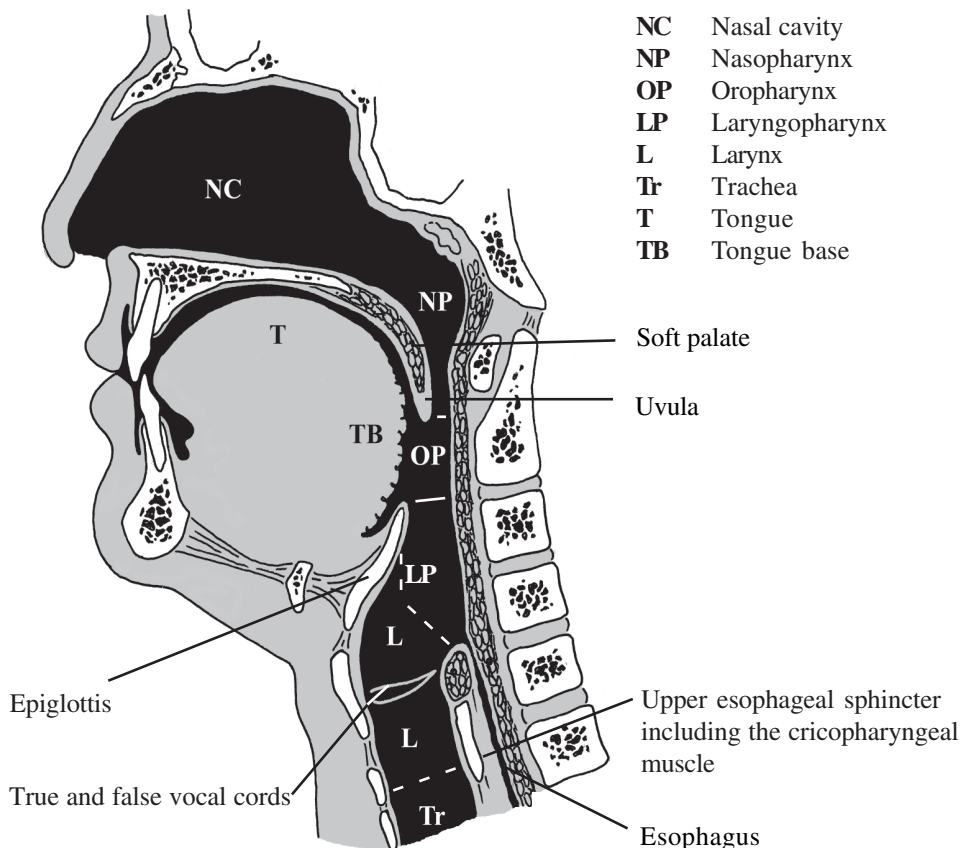


Figure 2.
 The pharynx.

The pharynx (Fig. 2)

The oral cavity and the nasal cavity are connected to the esophagus and the larynx via the pharynx. The pharynx is a muscular tube, and an important crossroad, through which both respiration and swallowing occurs. Furthermore, the pharynx participates in speech, snoring, coughing, gagging, and vomiting. The pharynx is divided into naso- (epi-) pharynx, oropharynx and laryngo- (hypo-) pharynx. The surface is covered with squamous cell epithelium, and lubricated by small salivary glands (Petrén, Carlsöö 1983, Sobotta 1994, Gaziano 2002).

Sensory and motor innervation of the oral cavity and pharynx

The second and third branches of the trigeminal nerve (V) are responsible for general facial sensation. The trigeminal nerve also provides the motor supply to the masticatory muscles and sensation to the oral cavity. The maxillary nerve provides sensation through different branches to the hard and the soft palate, and the mucous membranes of the pharyngeal pillars, and through a plexus at the bottom of the maxillary sinus, all the teeth

in the upper jaw, the gingiva, and the rear part of the mucous membranes of the bucca. The mandibular nerve provides sensation to the teeth and the gingiva in the lower jaw, the inside of the cheek, the tongue, and the floor of the mouth via the lingual nerve, and to the pharyngeal inlet. The chorda tympani joins the lingual nerve from the facial nerve (VII), and adds parasympathetic secretion to the submandibular and the sublingual salivary glands. The glossopharyngeal nerve (IX) innervates the tonsils, the pharyngeal pillars, the rear parts of the soft palate, and the sides of the tongue base, and provides motor function to the pharyngeal constrictors: most of the swallowing reflex is elicited via this nerve. The vagus nerve (X) also contributes to the innervation of sensation of the pharynx and the mucous membranes of the larynx, and also motor function to the soft palate, pharynx, larynx, and esophagus. The hypoglossal nerve (XII) controls motor function to the tongue. (Perlman 1991, Gaziano 2002, Berkowitz 2002).

SWALLOWING FUNCTION AND DYSFUNCTION

Normal swallowing function

A swallow is a dynamic process and can conveniently be divided into oral preparatory phase, oral transport phase, pharyngeal phase, and esophageal phase.

The oral and pharyngeal phase of swallowing

Mastication of a bolus is a voluntary process, and can be consciously inhibited. The tongue is the conductor, distributing the food items from side to side, to be blended with saliva, and processed by the teeth. The bolus is gathered on the top of the tongue, in a groove in the tongue base and, as the tongue base elevates, the bolus is forced back to elicit the swallowing reflex, when passing the area of the pharyngeal pillars. As the second stage of swallowing is initiated, a series of involuntary, rapid coordinated events occur. The duration of the pharyngeal swallowing phase is approximately 1.5 second (Curtis *et al.* 1984). Respiration is inhibited by reflex, with the velum rising and sealing off the nasopharynx. The hyoid bone and larynx move upward and forward. The movement folds the epiglottis, thereby protecting the laryngeal inlet. The true and the false vocal cords adduct, and constitute the most important protection from aspiration of the bolus. The bolus is transported through the pharynx where a sequential wave of contractions carries the bolus to the upper esophageal sphincter. The upper esophageal sphincter relaxes and when the bolus has passed, all structures involved resume position and respiration is no longer inhibited. When the swallowing reflex is elicited, the swallow cannot be inhibited. The tongue is a fundamental organ for normal swallowing, and it participates not only in the oral preparatory phase, but also in the dynamic pharyngeal phase of swallowing. Studies have shown that an adult swallows on average 35 times per hour while awake, and six times per hour while asleep, a total of approximately 580-2400 swallows in a 24-hour period (Lear *et al.* 1965, Miller 1982, Perlman 1991, Berkowitz 2002).

The swallowing reflex

The swallowing reflex is probably triggered from more than one specific area. The pharyngeal pillars, dorsal surface of the tongue, soft palate, and laryngeal surface of the epiglottis have been suggested (Miller 1982). The branches of three cranial nerves are

involved in the afferent part of deglutition: The trigeminal nerve (V), the glossopharyngeal nerve (IX) and the vagus nerve (X). The glossopharyngeal nerve exerts the strongest influence. The trigeminal (V), the facial (VII), and the hypoglossal (XII) nerves conduct efferent control. The swallowing reflex center is part of the reticular formation in the medulla oblongata of the brainstem (Miller 1982). It receives afferent impulses from the peripheral receptors to the central nervous system, and elicits the pharyngeal stage of the swallow. It programs the neuromuscular components (Perlman 1991).

Dysphagia

Dysphagia is defined as difficulty swallowing. Dysphagia is a symptom (Salassa 1999). Swallowing difficulties constitute not only a physical, but also a social and mental handicap (Tibbling 1996), since eating in the company of others is common in social life. Alimentation can be provided artificially, through a gastric fistula, but it is considered a severe handicap, and can result in withdrawal from social life. Neurologic disturbances are, by far, the most common etiology of dysphagia, but abnormal anatomy, neoplastic growth, and postoperative conditions can also cause dysphagia (Linden-Castelli 1991).

Signs and symptoms of oral or pharyngeal dysphagia

1. Coughing or choking with swallowing
2. Oral or pharyngeal regurgitation
3. Food sticking in the throat
4. Drooling
5. Unexpected weight loss
6. Change in dietary habits
7. Recurrent pneumonia
8. Change in voice and speech
9. Nasal regurgitation

(Palmer *et al.* 2000)

Swallowing dysfunction

Dysfunction is defined as impaired or abnormal function. Swallowing dysfunction can be symptomatic or asymptomatic, and can be objectively evaluated. Aspiration of solid food can cause fatal airway obstruction. Aspiration of small food items or beverages into the airway is a dangerous consequence of swallowing dysfunction, if it is silent and does not evoke a cough. Aspiration can lead to pneumonia, and repeated pneumonia is destructive to lung tissue (Langmore 1991) and can be potentially life-threatening. There are two pulmonary clearance mechanisms: Cough and ciliary action. Aspiration in the healthy person causes a vigorous cough. Ciliary function transports harmful agents out of the airways. Some patients are more vulnerable to silent aspiration and some are more tolerant (Palmer *et al.* 2000). Another manifestation of swallowing dysfunction is premature leakage, implying that the bolus leaks into the pharynx without eliciting the swallowing reflex with a risk of aspiration since respiration is not inhibited. Velar dysfunction, when the soft palate fails to seal off the nasal cavity

during the swallow, results in a risk of bolus penetration into the nasal cavity. Other signs of dysfunction are malfunction of the epiglottis, deficient bolus propagation, incomplete or uncoordinated opening of the upper esophageal sphincter, and penetration of the bolus into the laryngeal vestibule, all of which increase the risk of aspiration. Furthermore, bolus residual in the postoperative defect or in the pharynx after termination of the pharyngeal swallowing sequence increases the risk of aspiration because respiration is no longer inhibited, in spite of bolus being present in the airway.

CANCER OF THE HEAD AND NECK

Cancer of the head and neck can appear on the lips, oral cavity, nasopharynx, oropharynx, laryngopharynx, larynx, maxillary sinus, nasal cavity, ethmoid sinuses, salivary glands, and the thyroid glands.

Oral and pharyngeal cancer; frequency and etiology

Ninety percent of oral and pharyngeal cancers are squamous cell carcinomas, but mucoepidermoid carcinomas, adenocarcinomas, adenoïdcystic carcinomas or sarcomas may occur as well as malignant melanomas and lymphomas. Oral and pharyngeal malignancies are not common, representing approximately 1.8 % of cancers reported in Sweden during the years 1960 through 1989. Cancer of the lips constituted 0.6%, intra-oral cancers 0.7%, and pharyngeal cancer 0.5% (Östman *et al.* 1995). In Sweden approximately 570 oral and pharyngeal cancers are diagnosed per year (Östman *et al.* 1995). Worldwide, more than 500,000 new cases are anticipated annually. The frequency is increasing, and oral and pharyngeal cancer continues to represent a serious public health problem. Cancer of the oral cavity is two to four times more likely to be found in the male than in the female, and higher rates are associated with age over 55 years (Ries *et al.* 2002).

Smoking habits have long been known to be a major risk factor in the development of oral and pharyngeal cancers. Barón and co-workers (1993) explored the joint effects of alcohol and smoking, in the risk of cancer development across sites in the upper aerodigestive tract. The larynx is exposed more to cigarette smoke than to alcohol, the esophagus is exposed more to alcohol than to cigarette smoke, and the oral cavity and pharynx are exposed to both. Oral and pharyngeal cancer is, in that respect, a preventable disease (Day *et al.* 2003). The prognosis is dependent on the early detection and the location and size of the tumor.

Tumor classification

The TNM-system according to UICC (International Union Against Cancer) is widely used to characterize tumor size, location and spread.

- T refers to the extent of the primary tumor. The tumor is graded T1 to T4 depending on location and size, with T4 representing the largest tumor extent, *i.e.* a T1 oral cavity cancer does not exceed 2 cm in size, while a T4 has invaded the cortical bone, the deep/intrinsic muscle of the tongue, the maxillary sinus, or the skin.

- N stands for the presence of metastases to the regional lymph nodes: N0-N3, with N1 representing an ipsilateral single metastasis not exceeding 3 cm, and N3 for metastases exceeding 6 cm. The number of pathologically positive regional nodes was an indicator of survival rate, according to the study by DeNittis and co-workers (2001).
- M stands for distant metastases of head and neck cancers. Distant metastases to the lungs or the liver are the most common.

The tumors range from poorly differentiated to well differentiated.

Therapeutic aspects

Curative treatment

Curative treatment of most head and neck tumors in Sweden often include a combination of preoperative radiotherapy and surgery, and most cancer clinics follow their own treatment protocols. Radiotherapy is given to prevent microscopic malignant spread. Surgery is performed to remove the macroscopic tumor. Both treatment modalities can cause irreversible sequelae, which have great impact on the patient's oral functions, such as mastication, swallowing and speech.

Palliative treatment

Cytotoxic drugs have been used as palliative treatment, to reduce the tumor burden and pain. Radiotherapy in lower doses can ease pain and discomfort in desolate cases. It is of particular value in cases of skeletal metastases (Kaasa *et al.* 1996).

Radiotherapy

Shortly after X-rays were identified by Roentgen in 1895, it was discovered, that normal tissues were heavily affected by radiation, and the idea that tumors of different origin might be treated with external beam radiation, evolved. In the thirties it was found that if radiation was given in fractionated doses, higher doses could be given, than if it was given in one dose (Coutard 1934).

In Sweden, fractions of two Gy per day, five days per week, up to 64 Gy has been the treatment of choice when utilizing external beam technique. The radiotherapy is given unilaterally or bilaterally, dependent on the risk for metastases (Fig. 3).

Radiotherapy effect on tumor cells and healthy tissues

The tumor cell undergoes uncontrolled cell proliferation, and radiation seeks to kill the tumor cell by causing cell damage. Proliferative tumor cells are more sensitive to radiation damage, than are healthy cells, but healthy cells are damaged too. The radiation effect depends on dose and time factors (Thames *et al.* 1990). Normal tissue effects may be dose limiting. It was established, that the least damage to healthy tissues took place, and the most effect on the tumor-cell was gained, when irradiation was given in fractions of 1.8 to 2 Gy per day, five days a week (Emami *et al.* 1991).

Adverse effects

Acute effects

Acute reactions to radiotherapy include nausea, insomnia, lack of appetite, depression, and pronounced fatigue (Hagopian 1996). The skin and the mucosa react with swelling, red spots,

edema and soreness. The sensitivity of the particular tissue depends on e.g. the vascularisation, oxygen tension and rate of proliferation. Injury to the cell membranes and intracellular edema are seen in the parotid glands two hours after irradiation (El Mofty, Kahn 1981).

Late effects

Changes of the blood vessels in the radiation field, are the most important, since they are destructive and irreversible. The initial swelling and edema of the intima progress to a thickening with fibrosis, leading to narrowing and eventual obliteration of the lumen. The blood supply to the tissues is decreased, and resistance to trauma and infection is lowered (Rubin, Doku 1976). Fibrosis of the skin, with decreased flexibility may evolve with time, as

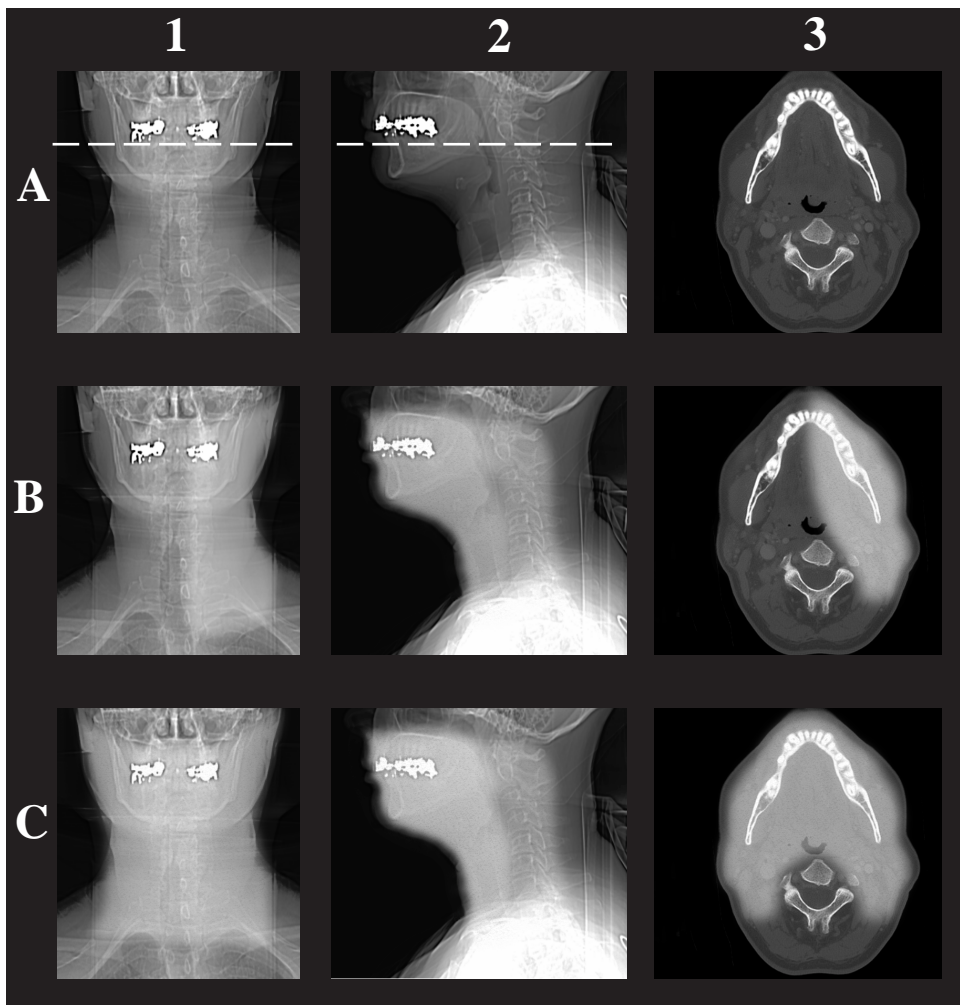


Figure 3.

Illustration of the radiation fields.

A. 1. Frontal view 2. Lateral view. 3. Axial view at the level of the broken line in 1 and 2.

B. Illustrates the range of the unilateral radiation field.

C. Illustrates the range of the bilateral radiation field.

well as teleangiectasias in the skin surface (Bentzen *et al.* 1989). Growth of hair and beard in the radiation field might stop. Body-fluid, normally drained by the lymphoid system, remain in the soft tissues, causing lymphedema, cosmetic, and functional derangement (Piso *et al.* 2001). The most radiosensitive of the salivary glands are the parotid glands, because they produce the serous secretions (El- Mofty, Kahn 1981). It is hypothesized that the glands themselves are not damaged, but that the radiation exposure causes damage to the blood vessels or nerves supplying the glands (Baum *et al.* 1985). Franzén and co-workers (1992) have also investigated the effect of radiotherapy on the parotid gland, and found the effect to be reversible after 52 Gy, but irreversible after 65 Gy. The muscles in the irradiated area lose their elasticity. The muscle fibers are replaced by fibrous tissue and mouth opening, for instance, is restricted as a result. Trismus evolves three to six months after the last radiotherapy session (Rubin, Doku 1976). Laurell and co-workers (2003) have reported strictures indicating fibrosis of the proximal esophagus after radiotherapy for head and neck carcinomas. Due to the impaired blood supply, necrosis may occur in adjacent bone (osteoradionecrosis), a longstanding necrotic process, complicated by infection. The mandible is predominantly affected (Beumer *et al.* 1972).

Nerves

Damage to the cranial and peripheral nerves after radiotherapy is uncommon, in contrast to the central nervous system (Kinsella *et al.* 1980, Leibel, Sheline 1987). However, data on radiation effects on the peripheral nervous system are scanty and often conflicting. Gillette and co-workers (1995) agree that late radiation injury to peripheral nerves is infrequently observed. Radiation causes acute and late effects. Acute damage reflects an interruption of normally homeostatic stem cells within the organ, whereas late damage involves changes within the supporting vascular and connective tissues. Acute damage is generally reversible and is not predictive of late damage. Late damage is usually progressive (Kinsella *et al.* 1980). Acute radiation damage to neurons and nerve endings probably results from direct radiation. Late radiation damage, at least partially, results from vascular injury in the nerve fiber. Small vessel obliteration rather than arterial infarction occurs in the nerve fiber. The proliferative capacity of the Schwann cell for remyelination is the principal repair mechanism of peripheral nerve damage. An impaired response of the Schwann cell due to radiation injury may contribute to late nerve damage. It has also been suggested that nerve compression secondary to fibrosis could be the mechanism of injury. The radiation response appears to vary with the components of nerve tissue studied. The neuron and nerve (axon) endings are more sensitive to radiation effects than the nerve fiber. Finally, a larger field results in more damage for a given dose but there is probably a dose-field size threshold. Radiation doses causing injury usually are greater than 60 Gy, when fractions of 1.8 Gy are used according to Giese and Kinsella (1991). Radiation damage to cranial nerves after curative radiation treatment to the head and neck field is rare. When it appears, it is complete and causes total nerve palsy (Takimoto *et al.* 1991).

Surgery

The aim of tumor surgery is to resect the tumor with a margin of healthy tissue. When the extent is decided, primary closure or reconstruction is planned. Surgery should be performed within one month following the last radiotherapy session since a statistically significant increase in post-operative infection and complications has been established with time elapsed between the last radiotherapy session and surgery.

Primary closure

The use of primary closure is dependent on the location of the tumor, whether the tumor is small enough and when resection is not too extensive. After resection, the remaining tissues are pulled together and sutured, causing reduction of tissue volume. Logeman and co-workers (1997) claim that primary closure gives the best swallowing and speech function, as compared with microvascular flap reconstruction.

Free radial forearm flap reconstruction

The development of microsurgical techniques has made it possible to transplant healthy tissues and skin flaps from other parts of the body, and to dissect and transport suitable lengths of blood vessels to the resection site. The blood supply to the transplanted tissue is secured when the vessels are anastomosed end-to-side to suitable larger vessels, or vessels of similar diameter end-to-end. Free flap reconstruction technique, developed during the late 70s and early 80s, is used in the head and neck area. The free radial forearm flap is the most commonly used. One surgical advantage is that surgery and reconstruction is a one-stage procedure. When postoperative radiotherapy is administered, the microvascular free flap tolerates radiation up to 70 Gy even in the early postoperative period. In cases of preoperative radiotherapy, the associated blood vessels are transferred with the tissues to irradiated areas, where the anastomoses can be performed to non-irradiated vessels in the neck. Even the afferent sensible nerve could be included and anastomosed to a suitable recipient nerve in the hope of regaining functional sensitivity. Healthy tissues are added to resection areas, and can be sutured to the resection area without tension or future scar formation. Together with the skin flap, a portion of radius bone, if needed, can be included. Morbidity at the donor site is most often low. The free radial forearm flap is thin and pliable, but often does not provide sufficient tissue volume for functional reconstruction. The surgical defect is only outlined and sensation or mobility is not provided to the resection area.

The pectoral major flap has commonly been used in reconstruction of the head and neck region (Croce *et al.* 2003). The pectoral muscle with its skin paddle is dissected, and through a tunnel in the soft tissues of the neck, it is transported and sutured to the resection area, without violating its blood supply.

Neck dissection

In the presence of regional metastases to the lymph nodes, radical neck dissection is carried out. Radical neck dissection includes not only the lymph nodes in the neck, but also the sternocleidomastoid muscle on the tumor side, and damage to the accessory nerve (XI) is not uncommon at surgery. Since most tumors are unilaterally located, unilateral neck dissection is most common. If the tumor is located in or in the vicinity of the midline, and if regional metastases are suspected, bilateral neck dissection is carried out. Modified neck dissection is considered sufficient, where no metastases are detected preoperatively (Talmi 1999). The procedure spares the sternocleidomastoid muscle.

Functional rehabilitation

Different strategies and maneuvers have been described in an effort to enhance swallowing capability in patients with swallowing dysfunction after treatment.

- Body postural changes
- Super-supraglottic swallow (Airway closure at the level of the arytenoids to the base of epiglottis)
- Supraglottic swallow (Voluntary closure of the vocal cords prior to the swallow. Breath-holding before and during the swallow. Cough afterwards)
- Mendelsohn's maneuver (Voluntary prolongation of laryngeal elevation and cricopharyngeal opening during swallow)

(Lazarus *et al.* 1993 a,b, Logemann *et al.* 1997a)

Prosthetic appliances

Obturator can offer structural support and compensate for oral and oropharyngeal structures that were lost or altered after surgery (Gaziano 2002), and palatal reshaping prosthesis can help re-contour or lower the palate to allow the remaining portion of the resected tongue to contact the palate when swallowing (Davis *et al.* 1987, Logemann 1994, Lazarus 2000).

Artificial alimentation

Need for gastric feeding could evolve due to mucositis and nausea during the radiotherapy treatment period. In patients, where swallowing disabilities after treatment are predicted, or diagnosed, gastrostomias like PEG (Percutaneous endoscopic gastrostomia) or Witzelfistulas are indicated. A gastrostomia consists of a permanent feeding tube installed percutaneously into the ventricle providing artificial alimentation.

Quality of life

Head and neck cancer has an enormous impact on a patients' quality of life (DeBoer *et al.* 1999) due to impact on the patients' appearance and oral and pharyngeal function. Psychosocial issues are important on the long list of factors affecting quality of life. Support and information on treatment sequelae are proven to have a clear positive effect on rehabilitation (Pruyn *et al.* 1986, De Boer *et al.* 1999).

BACKGROUND TO THIS PROJECT

The oral cavity serves as the entrance to the digestive canal and is an important sensing device. In the oral cavity, food is prepared for further digestion, and beverages are contained before being swallowed. The tongue is the central organ in the oral cavity, and acts as the conductor in the act of swallowing. Speech articulation and mastication are other important oral cavity functions. The pharynx serves as the continuation of the feeding tube. It is a crossroad, where air inhaled from the nasal cavity, passes down the pharynx via the larynx to the lungs. When swallowing, respiration is inhibited by reflex to prevent aspiration into the airway. When eating, food and beverage is transmitted down through the pharynx towards the upper esophageal sphincter. As the bolus passes through, the pharyngeal phase of swallowing is completed, and respiration is resumed (Gaziano 2002, Miller 1982, Perlman 1991).

Cancer in this delicate area is considered a life-style disease, in that smoking and alcohol are important etiological factors (Barón *et al.* 1993, Day *et al.* 2003). Patients are commonly in their sixties (Ries *et al.* 2002). Cancer as well as the treatment of cancer has a significant negative impact on all oral functions (Rogers *et al.* 2002), such as speech and swallowing (Lazarus 2000, Pauloski *et al.* 2002). In the most serious cases of dysphagia and swallowing dysfunction, life-long gastric feeding has to be utilized because of alimentation inability, aspiration or prolonged feeding time. As the pleasures of the table become more and more important with age, the patients' quality of life is highly challenged (DeBoer *et al.* 1999, Talmi 2002, Schliephake, Jamil 2002).

Since the surgical sequelae after treatment are obvious, little attention has so far been directed to possible deterioration of sensation following radiotherapy (Aviv *et al.* 1992). In the ongoing process of improving not only survival rates, but also the quality of life for those who survive (Gillette *et al.* 1995), it is important to evaluate different treatment modalities, and to explore the consequences of different treatments. When the total morbidity from the different treatment modalities has been explored, and when evaluation of the sequelae influencing oral functions are well founded, the treatment causing the least morbidity can be chosen. In order to give adequate pretreatment information, and in an effort to develop meaningful posttreatment rehabilitation strategies, the entire range of sequelae must be known. In this spirit, the present thesis was conducted.

AIMS

This thesis comprises a retrospective part (I) and an inception, prospective, long-term follow-up (II-V) with the comprehensive aim of elucidating adverse effects on swallowing function, induced by radiotherapy and surgery for malignant tumor in the oral cavity or pharynx.

The specific objectives were:

- to make an inventory of surgical and functional sequelae after radiotherapy, tumor resection, and reconstruction with a free radial forearm flap (I).
- to assess intra-oral sensation on the tumor side and on the non-tumor side before and after uni- or bilateral radiotherapy (IV).
- to evaluate the ability to discriminate size and shape intra-orally before and after treatment (II, III).
- to evaluate the degree of swallowing impairment following radiotherapy and surgery (V) and
- to explore any significant association between the degree of swallowing dysfunction and the degree of decline in size and shape discrimination and the degree of sensory impairment following treatment (V).

MATERIAL

Patients

The material in total was comprised of 138 patients, 90 males and 48 females, ranging from 25 to 85 years of age (mean age 60 years, median 61 years). All patients were diagnosed and treated for malignant tumors in the oral cavity and pharynx at the department of Oto-Rhino-Laryngology, often in collaboration with the department of Plastic and Reconstructive Surgery and Radiumhemmet, at the Karolinska University Hospital, Stockholm, Sweden.

The retrospective material (I) included 99 consecutive patients. Ninety patients suffered from squamous cell carcinoma, five had adenoid cystic carcinoma, two had muco-epidermoid carcinoma, one patient a Merckel cell tumor, and one a basalioma. For TNM tumor classification, see Table I. Eighty-four patients were preoperatively treated with 50 Gy (n= 23) or 64 Gy (n= 61), 58 bilaterally and three unilaterally. Three patients were given 64 Gy radiotherapy postoperatively. Twelve patients received no radiotherapy, 10 because they had radiotherapy to the head and neck earlier in life, and in two patients no radiotherapy was indicated. The tumors were resected, and the patients had reconstruction with free radial forearm flaps in a one-stage operation.

The prospective material (II - V), was comprised of consecutive patients, diagnosed with squamous cell carcinoma in the oral cavity or the pharynx during 1989 through 1996. Patients were excluded if the disease recurred or generally spread, and when conditions indicated an inability to participate in all tests throughout the study period. The remaining 39 patients were subdivided in an oral (n=14) and a pharyngeal (n=25) group based on the location of the tumor. Thirtyfour patients had unilateral tumors. Five patients had a tumor

Table I.

The regional distribution and T-classification of 93 patients. Tumors in six patients were not classified.

Region	T1	T2	T3	T4	Total
<u>Oral group</u>					
Buccal		1		1	2
Maxillary gingiva				2	2
Mandibular gingiva				14	14
Floor of the mouth	1	8	3	5	17
Mobile tongue	1	3	3	4	11
Retromolar region			1	1	2
<u>Pharyngeal group</u>					
Faucial arch			2	1	3
Base of tongue	1	9		5	15
Tonsil	1	6	4	7	18
Hypopharyngeal wall	3	3	1	2	9
Total	7	30	14	42	93

in the midline, engaging both sides. The regions and the clinical TNM tumor staging according to the UICC classification are seen in Table II, as are additional patient data. The patients received radiotherapy treatment to 64 Gy, 38 preoperatively and one postoperatively. Radiotherapy was bilateral in 29 patients and unilateral in 10 (Fig. 3). Thirty-two patients had surgery, with one patient dying shortly after surgery.

Fifteen patients, five women and 10 men between 50 and 74 years of age, (mean 63 years, median 66 years), participated in all the prospective examinations and tests (II-V), Table II.

Reference individuals

A group of 20 healthy reference individuals, 10 men and 10 women were age-matched to the patients and participated in the three prospective tests twice, at a two month interval (II - IV). Their age was between 49 and 70 years (mean 60 years, median 58 years). The reference individuals had no functional deficits regarding mastication, swallowing and speech, nor did they have a history of malignant disease of the oral cavity or pharynx.

METHODS

Retrospective part

Swallowing, speech impairment and surgical complications were evaluated in patients reconstructed with free radial forearm flaps (I). Patient data on surgical outcome, functional sequelae on swallowing and speech, and other complications were obtained from the medical records. Swallowing function was evaluated as unchanged, restricted to puréed and liquid food, or impeded to the extent that gastrostomias were needed. Speech intelligibility and quality was noted.

Prospective part

In the prospective part of the study, patients' identification of hole size (II) and shape (III) was tested, as was their intra-oral sensation (IV). Swallowing function (V) was cineradiographically evaluated. All tests and examinations on patients were performed on four occasions: (1) after diagnosis, before treatment, (2) after 64 Gy, preoperative radiotherapy, before surgery, (3) six months after radiotherapy and surgery and (4) one year after radiotherapy and surgery (Fig.4).

The healthy reference individuals were tested on intra-oral hole size identification (II), shape recognition (III), and sensation with von Freys' hairs (IV) on two occasions with two month interval.

Every intra-oral test was conducted twice on every test occasion. The same examiner performed all intra-oral testing, and the same radiologist performed all radiographic examinations of the swallowing sequences. Patients and reference individuals with dentures were assessed without their dentures, except during the radiographic swallowing examination (V). Patients or reference individuals were never informed of the test results at any time.

Comparisons were performed inter- and intra-individually (II-V) and between groups (II,III) and to the healthy reference individuals (II-IV).

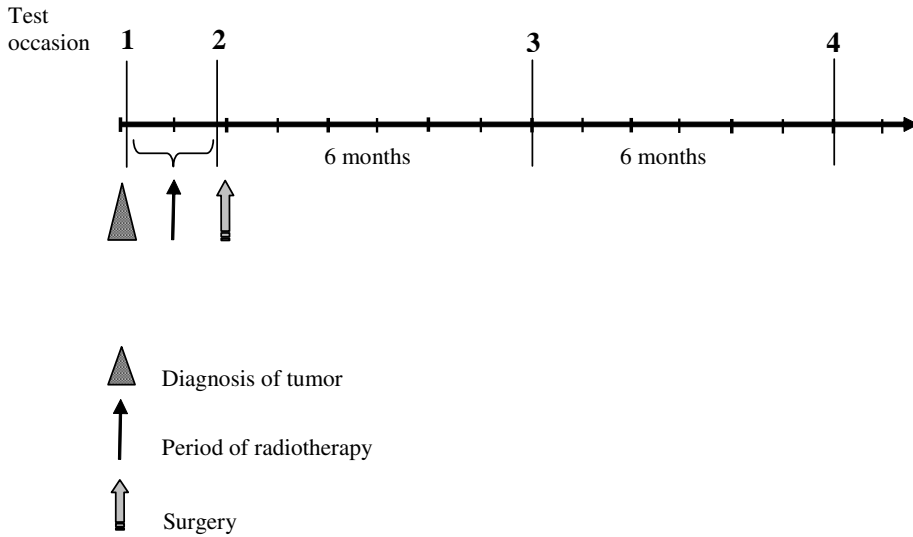


Figure 4.

The tests were performed: 1. after diagnosis, before treatment. 2. within one month after the last radiotherapy session. 3. six months after surgery. 4. twelve months after surgery.

Hole size identification test

The patients (n=31) and the reference individuals were tested in intra-oral hole size identification of test tools (II). The test tools were five acrylic discs, 25 mm in diameter and 5 mm thick with a small plastic rod attached to facilitate handling. A hole with a diameter of 1, 3, 5, 7, or 9 mm was drilled through the center of each disc (Fig. 5a). Each subject was requested to close her/his eyes, while the examiner placed each disc, chosen randomly one at a time, into the subject's mouth. If the subject recognized the presence of a hole in the disc the subject was then instructed to open her/his eyes, hold the handle attached to the disc, and to explore the hole in the center of the disc.




Figure 5a.

The five hole size test tools, with holes of 9, 7, 5, 3 and 1 mm diameter.

Table II. The distribution of sex, age, tumor region, TNM-classification and treatment among 39 patients treated for malignant tumors in the oral cavity or pharynx.

Pat no.	Age (y)	Sex	Tumor Region	Tumor Side	Tumor Size	Radio therapy	Surgery	Lingual nerve resection
Pharyngeal group								
1	66	F	Hypopharynx	R	T2 N0	R+L	FF	
2	51	M	Soft palate	R	T2 N0	R+L	Pc	
3	60	F	Soft palate	RL	T3 N1	R+L		
4	55	M	Tonsil	R	T3 N3	R+L	FF	R
5	68	F	Tonsil	L	T4 N0	R+L	Pc	L
6	61	M	Tonsil	R	T2 N1	R+L	#	
7	59	F	Tonsil	R	T4 N1	R	FF	R
8	67	M	Tonsil	L	T3 N3	R+L	Pc	
9	55	F	Tonsil	L	T2 N1	R+L	FF	L
10	54	F	Tonsil	R	T4 N1	R+L	FF	R
11	44	M	Tonsil	R	T3 N0	R+L	#	
12	63	M	Tonsil	L	T3 N0	R+L	#	
13	58	M	Tonsil	R	T3 N0	R+L	#	
14	58	M	Tonsil	R	T4 N2	R+L	FF	R
15	62	M	Tonsil	R	T2 N2	R	#	
16	50	M	Faucial arch	R	T3 N1	R	(FF)	R
17	45	M	Base of tongue	L	T4 N0	R+L	FF	L
18	51	F	Base of tongue	L	T1 N2	R+L	FF	L
19	62	M	Base of tongue	R	T2 N0	R+L	FF	R
20	49	M	Base of tongue	R	T2 N2	R+L	#	
21	74	M	Base of tongue	R	T2 N0	R	Pc	
22	73	F	Base of tongue	L	T2 N0	R+L	FF	L
23	60	M	Base of tongue	L	T1 N0	R+L	Pc	
24	69	M	Base of tongue	L	T4 N0	R+L	FF	
24	62	M	Base of tongue	R	T4 N1	R+L	FF	
Oral group								
26	68	M	Retromolar trig	L	T4 N1	L	Pc	L
27	52	M	Retromolar trig	L	T4 N0	L	(FF)	L
28	54	M	Floor of mouth	RL	T2 N1	R+L	FF	
29	69	F	Floor of mouth	R	T2 N0	R+L	Pc	R
30	64	M	Floor of mouth	RL	T4 N0	R+L	PMF	L
31	66	F	Gingiva, lower jaw	RL	T4 N1	R+L	FF	R+L
32	69	F	Gingiva, lower jaw	RL	T4 N0	R+L	FF	L
33	68	F	Gingiva, lower jaw	R	T4 N0	R	Pc	R
34	58	M	Gingiva, lower jaw	L	T2 N1	L	Pc	
35	65	M	Mobile tongue	L	T2 N0	R+L	Pc	
36	50	M	Mobile tongue	R	T3 N0	R+L	FF	R
37	50	F	Mobile tongue	R	T2 N0	R+L	Pc	R
38	65	F	Bucca	L	T2 N1	L	(FF)	
39	72	M	Bucca	L	T2 N0	L	Pc	

R= Right, L= Left, RL= Midline tumor, engaging both sides, FF= Free Flap, (FF)=Necrosis of Flap, Pc= Primary closure, PMF= Pectoral Major Flap, #= No surgery, due to complete response to radiotherapy. Pat. 32 participated in hole size tests only.

Mandibular discontinuity (reconstruction)	Swallow test participation				Hole size, shape test participation				Sensation test participation			
	1	2	3	4	1	2	3	4	1	2	3	4
Broken	X	X	X	X	X	X	X	X	X	X	X	X
	X	X	X	X	X	X	X	X	X	X	X	X
	X	X			X	X						
	X	X	X	X	X	X	X	X	X	X	X	X
	X	X			X	X	X	X	X	X	X	X
Broken	X	X	X	X	X	X	X	X				
	X	X	X		X	X	X		X	X		
	X		X	X	X	X	X	X				
	X	X	X	X	X	X	X	X				
	X	X	X	X	X	X	X	X				
Split rib					X	X			X	X		
					X	X			X	X		
									X		X	X
									X	X		
									X	X		
Broken	X	X	X	X	X	X	X	X	X	X	X	X
	X	X	X	X	X	X	X	X				
	X	X	X	X	X	X	X	X				
	X	X	X	X	X	X	X	X	X		X	X
	X	X			X	X			X	X		
Split rib	X	X	X	X	X	X	X	X	X	X	X	X
	X		X	X	X		X	X	X		X	X
	X	X	X	X	X	X	X	X	X	X	X	X
	X	X	X	X	X	X	X	X	X	X	X	X
	X	X	X	X	X	X	X	X	X	X	X	X
Fibula	X	X			X	X	X	X	X	X	X	X
	X	X	X	X	X	X	X	X	X	X	X	X
	X	X	X	X	X	X	X	X	X	X	X	X
	X	X	X	X	X	X	X	X	X	X	X	X
	X	X	X	X	X	X	X	X	X	X	X	X
Split rib	X	X	X	X	X	X	X	X	X	X	X	X
	X	X	X	X	X	X	X	X	X	X	X	X
	X	X	X	X	X	X	X	X	X	X	X	X
	X	X	X	X	X	X	X	X	X	X	X	X
	X	X	X	X	X	X	X	X	X	X	X	X
Split rib	X	X	X	X	X	X	X	X	X	X	X	X
	X	X	X	X	X	X	X	X	X	X	X	X
	X	X	X	X	X	X	X	X	X	X	X	X
	X	X	X	X	X	X	X	X	X	X	X	X
	X	X	X	X	X	X	X	X	X	X	X	X

The subjects' task was to identify the size of the hole perceived in the disc and to point out the circle with identical diameter on a placard illustrating an array of blackened circles with diameter 0.5, 0.75, 1.0, 1.5, 2.0, 2.5...12 mm (Fig. 5b). The subjects' performance for each of the five holes was recorded and analyzed as correct, under- or overestimation of the true size. There were no time constraints, and subjects could explore the hole in the disc as long as necessary in order to arrive at a decision. The divergence between the subjects' answer and the true size was given scores, where one score corresponded to the difference between two close filled circles on the visual comparator array (0.5 mm). The sum of the scores from the repeated test on each test occasion constituted the result. In addition, the over- and underestimations in relation to the true size were registered for every test occasion.

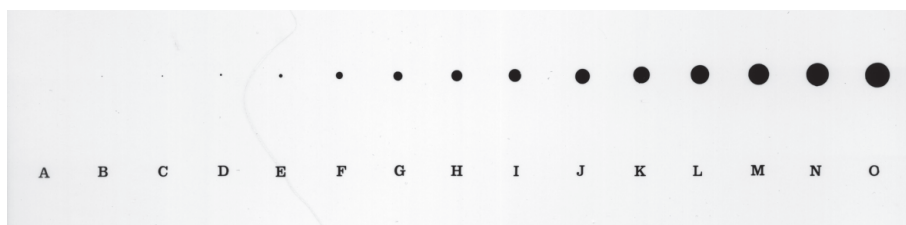


Figure 5b.

The hole size identification placard.

Shape recognition test

The patients (n=30) and the reference individuals were tested in intra-oral shape recognition of test tools (III). Five different discs of five mm thick acrylic were fabricated. They were circular, square, triangular, a four-pointed star, and a five-pointed star (Fig. 6a). Each acrylic disc was attached to a small plastic rod to facilitate handling and cleaning. Each subject was asked to close her/his eyes while the examiner randomly placed each of the five shapes in the subject's mouth.




Figure 6a.

The five shape test tools: a circle, a triangle, a five-pointed star, a square and a four-pointed star. All test tools were regular in shape.

The subject was instructed to hold the handle and manipulate the object in any fashion until she/he could verbally describe the shape of the object. In cases in which the object was perceived as irregular in shape or difficult to express in words, a simple drawing was accepted (Fig. 6b). The number of subjects' incorrect answers to the repeated test, formed the result.

Performance in hole size identification and shape recognition was analyzed with regard to tumor site, oral and pharyngeal groups and tumor size; the T1 and T2 tumor groups were compared to the T3 and T4 tumor groups. The test results were also analyzed relative to whether the radiotherapy was uni- or bilateral. The results in patients with surgical lingual nerve damage as documented in the operation records, were also compared to those in patients with no postsurgical damage to the lingual nerve.

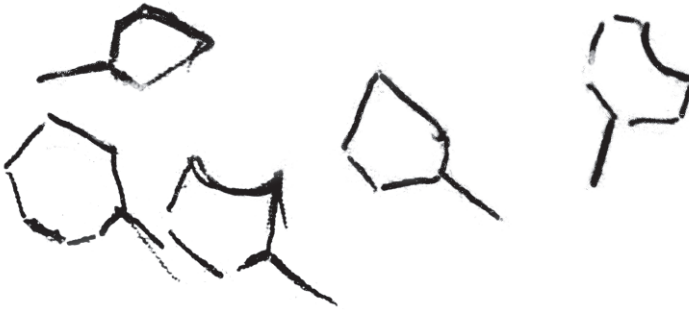


Figure 6b.

A patient's misapprehension of the shape of the five-pointed star at test occasion 3, six months after radiotherapy and surgery.

Test of intra-oral sensation with von Frey hairs

The patients ($n=27$) and the healthy reference individuals were bilaterally tested at three fixed intra-oral sites (IV): the lateral hard palate, the lateral dorsum of the mobile tongue, and under the tongue, at the side of the floor of the mouth. To identify the lightest pressure that the subject could perceive as touch, von Frey hairs (Semmes-Weinstein monofilaments) were used. They consisted of acrylic rods equipped with fine monofilaments of varying thickness (Fig.7). These filaments bend at a certain pressure. During the von Frey hair testing, the subject was seated in an upright position with eyes closed and mouth open. Testing began on the non-tumor side. The filaments were applied in descending order of thickness until the patient could no longer perceive any sensation. The application of the filaments was then continued in an ascending order, until the filament force again could be perceived. Thresholds were noted and the entire procedure was undertaken four times. The mean value for each test site was established for every test occasion. As a placebo test the filament was occasionally not applied, and if the subject reported a pressure sensation, he was told to open his eyes, and a full explanation of the testing procedure was repeated. Then the entire testing procedure was undertaken again in accordance with Henkin and Banks (1967).




Figure 7.

The von Frey hair testing kit, the brush, the sharp probe, the metal rolls and a heater, for heating the metal roll to 44°C.

Test of intra-oral sensation with light brush, pin prick, heat and cold

In addition the patients (n=27) were tested bilaterally at the same three fixed intra-oral sites with light brush, pin prick, heat and cold (IV). A camelhair-brush was used for light brush testing. Nociceptive perception was tested by pin prick with a sharp probe and thermal discrimination with metal rolls of 44°C and 28° C (Fig. 7). When testing, the patients were introduced to the test tool on the non-tumor side first as the norm and then on the tumor side for comparison. Their decision was whether they felt stronger, weaker, or similar sensation on the tumor side compared to the opposite non-tumor side.

Radiography

The patients (n=26) were cineradiographically examined, before and after treatment, to assess oral and pharyngeal swallowing function (V). For participation see Table II. Two sets of radiographic equipment were used, both were sphygmometers with cineradiographic cameras triggering exposures and information stored on 35 mm film and on videotape. The patient's head was gently supported in a position comfortable for swallowing with examinations performed in the lateral and the posteroanterior projection.

The oral cavity and the pharynx were first depicted during swallowing of a liquid bolus consisting of 10 ml iodinated contrast medium (Dionosil, Glaxo U.K.) administered with a spoon. In the absence of aspiration, the examination was extended to include the intra-oral preparation of a solid bolus and the pharyngeal swallowing phase. The solid bolus consisted of a mixture of gelatin and iodinated contrast medium (Omnipaque, Nycomed, Sweden) approximately 1 cm³ in size. Each swallowing sequence was repeated at least once. At evaluation, the cine-films and the videotapes were run back and forth at full speed, and in slow motion and the authors interpreted the radiographic recordings individually and in consensus.

The evaluation included the oral bolus preparation, pharyngeal swallowing function, pharyngeal anatomy, and pathology. Swallowing dysfunction was classified as (I) premature leakage if the bolus entered the pharynx without eliciting the swallowing reflex. Leakage had to be repeated at least once to be considered dysfunction, (II) velar dysfunction if the soft palate failed to seal off the nasopharynx when the swallowing reflex was elicited. This could occur with or without nasal regurgitation, (III) epiglottal dysfunction if the epiglottis failed to fold and close the laryngeal vestibule during bolus transit through the laryngopharynx, (IV) deficient bolus propagation, (V) dysfunction of the upper esophageal sphincter, if the opening of the sphincter was incomplete (less than 50% of the lumen) or uncoordinated with the peristaltic wave, (VI) penetration if the bolus entered the laryngeal vestibule but not below the vocal cords, (VII) aspiration if the bolus penetrated below the vocal cords, (VIII) bolus residual if bolus remained in the postoperative defect or the pharynx after the swallowing sequence was completed, (IX) inability to swallow any type of bolus.

Swallowing function was classified as normal, mild dysfunction, moderate dysfunction, severe dysfunction, or inability to swallow. A five-stage grading of swallowing function and dysfunction was used:

1. Normal swallowing function.
2. Mild swallowing dysfunction; in the presence of one of the following deviant features: Premature leakage, residual, or laryngeal penetration.
3. Moderate swallowing dysfunction: Two or more of the deviant features in grade (2) or dysfunction of the upper esophageal sphincter, the epiglottis or the propagation wave.
4. Severe swallowing dysfunction: Aspiration with or without cough.
5. Inability to swallow.

Swallowing function versus intra-oral sensation and discrimination ability

The 15 patients who had participated in all prospective tests and examinations were statistically evaluated regarding the degree of swallowing dysfunction and the decline in sensory impairment and discrimination ability.

Statistics

Pearson's correlation coefficient was used to evaluate linear associations between infection rate and time elapsed after the last radiotherapy session (I).

Fisher's exact test was used to evaluate thrombosis frequency before and after the administration of heparin (I).

Differences in hole size identification (II), shape recognition (III), filament force (IV), and changes within groups between test occasions were evaluated with the Wilcoxon signed-rank test.

At specific test occasions, differences in hole size identification (II), shape recognition (III), filament force (IV), and between groups, sites, and sides were evaluated with the Mann-Whitney (Wilcoxon rank sum) test.

At test occasion one, the Kruskal Wallis test was used to evaluate differences in filament force between the reference, the oral, and the pharyngeal groups (IV).

The Marginal homogeneity test was used to compare the results of light touch, pin prick, heat and cold tests from different test occasions (IV).

The association between the degree of swallowing dysfunction and intra-oral sensation, shape recognition and hole size discrimination, respectively, was tested with Spearman's Rank-Order Correlation Coefficient (ρ).

The patients and reference individuals gave informed consent to participate in the study, which was approved by the Ethics Committee at the Karolinska University Hospital, Dnr. 89:97.

RESULTS

RETROSPECTIVE PART

Posttreatment sequelae

The retrospective study (I) revealed that the postoperative swallowing capacity was restricted to the amount that gastric fistulas had to be used in 31 (31 %) patients. Fifty-six patients (57%) could swallow puréed and liquid food, while swallowing was unrestricted in 8 (8%). Information was lacking in four (4%) patients. The patients treated for the largest tumors had the greatest feeding problems. The frequency of aspiration pneumonia was 21%. Five (5%) patients reconstructed with small flaps suffered no decline in speech quality, while the remaining 94 (95%) patients had speech deviation noted in their files. In general, the intelligibility was greater for connected speech than for individual sounds.

There was a statistically significant increase in the frequency of postoperative infectious complications (37%) with time elapsed from the last radiotherapy session ($p=0.03$). With the administration of per- and postoperative heparin, the initial frequency of general embolism (13%) decreased to zero; a significant difference ($p=0.011$). In seven percent reoperation took place within 24 hours, due to impaired flap circulation. The cause was hemorrhage in two percent, the veins were twisted in two percent, one percent had thrombosis, and in two percent normal conditions were noted. The frequency of complete necrosis was six percent.

PROSPECTIVE PART

Intra-oral hole size identification

Compared to test results after radiotherapy the oral cancer group had significant decline in hole size identification ($p=0.03$) (II), six months after radiotherapy and surgery. No improvement was detected one year after treatment. The pharyngeal cancer group had no deterioration in hole size identification following treatment. Resection of the lingual nerve at surgery was approximately as common in both groups: 60% and 73% respectively. Among the healthy reference individuals there was no significant difference in performance between the two test occasions, nor in comparison to the patients at test occasion one.

Intra-oral shape recognition

In the shape recognition test, a learning effect was expected and demonstrated among the healthy reference individuals at the second test occasion (III). The reference individuals judged shapes correctly significantly more often at the second test occasion ($p=0.004$) two months after the first test. No such learning effect was found among the patients at test occasion two. After radiotherapy, the patients showed no statistically significant change in performance. Test results deteriorated significantly six months after radiotherapy and surgery in both the oral ($p=0.04$) and the pharyngeal ($p=0.009$) cancer group in comparison to test occasion two, before surgery. No significant recovery was seen one year after treatment.

Intra-oral sensation

Intra-oral sensation tested with von Frey hairs (IV) was demonstrated not to decline significantly when tested within one month after preoperative radiotherapy and compared to test occasion one. Intra-oral sensation declined significantly on the tumor side six months following radiotherapy and surgery ($p<0.001$), and in addition, on the opposite non-tumor side if the patient received bilateral radiotherapy ($p=0.001$), when compared to test occasion one (IV). There was no significant decline on the opposing, non-tumor side, when radiotherapy was restricted to the tumor side only (Fig. 8). No significant improvement in intra-oral sensation was seen one year after treatment. The association between postoperative sensory loss on the tumor side and resection of the lingual nerve at surgery was significant ($p<0.001$).

Among the reference individuals there was no significant difference in performance between the two test occasions, nor in comparison to the patients at test occasion one.

Intra-oral sensation was also tested with light brush, pin prick, heat and cold six months after treatment. Compared to test occasion one, there was significant decline on the operated side: Light brush: $p=0.003$, pin prick: $p=0.003$, heat: $p<0.001$, cold: $p<0.001$ (IV). There was also a significant association in patients with surgical resection of the lingual nerve: Light brush $p=0.013$, pin prick $p=0.001$, heat $p<0.001$, cold $p<0.001$.

There was a significant association between the decline in intra-oral sensation and deterioration in shape recognition ($p<0.001$, $\rho\ 0.285$), and also between the decline in intra-oral sensation and deterioration in hole size identification ($p<0.001$, $\rho\ 0.209$).

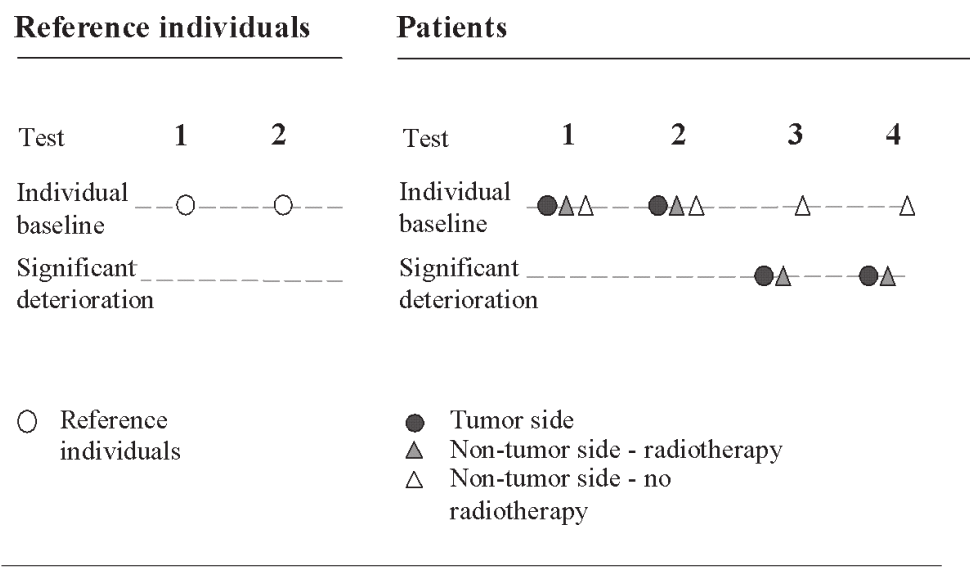


Figure 8. Schematic illustration of the impact of radiotherapy and surgery, on intra-oral sensation, in patients with oral and pharyngeal cancer. Reference individuals for comparison. Test of sensation performed with von Frey hairs.

Dysphagia

At the inceptive radiographic examination before treatment (V), all patients were capable of normal alimentation, although some patients complained of e.g. choking at meals. One year after treatment, 40 % (10/25) were provided with gastric fistulas or nasogastric feeding tubes due to difficulty swallowing. Fifty-two percent of the patients (13/25) reported they could only manage oral intake of puréed and liquid food, and 8% (2/25) managed normal alimentation.

Radiography

Swallowing dysfunction

At the inceptive examination, prior to treatment, 26 patients were examined (V). Ten patients demonstrated normal swallowing function, 11 mild swallowing dysfunction, and four moderate swallowing dysfunction. One patient with a tumor in the laryngopharynx suffered from severe dysfunction. After preoperative radiotherapy, the swallowing capability of four patients declined. Three declined from normal to mild dysfunction, and one from mild to moderate dysfunction. The swallowing function of three patients improved, one from mild to moderate dysfunction, one from mild dysfunction to normal function, and the swallowing of the patient with laryngopharyngeal cancer normalized due to good response to radiotherapy.

Six months after surgery, four patients were incapable of swallowing, 10 patients demonstrated severe dysfunction, 10 moderate, and one mild dysfunction. One patient had normal swallowing function. Compared with the inceptive examination, swallowing deteriorated in 22 patients. The patient with cancer in the laryngopharynx declined again to moderate dysfunction six months following surgery.

One year after surgery one patient was deceased. Four patients were still incapable of swallowing. Among the 21 patients who could perform a swallow, dysfunction was severe in 10 patients, moderate in seven and mild in four. Comparison between the examinations six months and one year following surgery, revealed that swallowing function deteriorated in four patients, improved in three, and remained unaltered in 18 patients, including the four patients who were incapable of any swallowing.

Of the ten patients with gastric feeding, nine had been reconstructed with free radial forearm flaps. One year after surgery, the mean grade of swallowing dysfunction was 3.9 in patients with free radial forearm flap reconstruction (n=15), and 3.1 in patients with primary closure (n=10). Residual in the surgical defect was present in 11 of the 15 (73%) patients reconstructed with a free flap and in four of the 10 (40%) patients treated with primary closure. Of the 18 patients, where surgery included lingual nerve resection, the mean grade of swallowing dysfunction was 3.7, and in the seven patients without lingual nerve resection, the mean grade was 3.1. The mean grade of swallowing dysfunction was 3.0 among the patients with unilateral radiotherapy treatment (n=6) and 3.7 among the bilaterally treated (n=19).

Swallowing function versus intra-oral sensation and discrimination ability

There was a significant association between the degree of swallowing dysfunction and decline in intra-oral sensation ($p<0.001$, $\rho=0.297$) and decline in shape recognition ($p<0.001$, $\rho=0.316$), respectively. There was no statistical significance in association between degree of swallowing dysfunction and decline in hole size identification.

Intra-oral sensation versus discrimination ability

There was a significant association between the intra-oral sensation decline and the deterioration in shape recognition ($p<0.001$, $\rho=0.285$), and also between the intra-oral sensation decline and the deterioration of hole size identification ($p<0.001$, $\rho=0.209$).

DISCUSSION

Inability to enjoy the delights of the table is considered by most people to be a huge restriction of life quality, even though the definition of quality of life is subjective, varies over time, among cultures, and among people of different socioeconomic levels (Talmi 2002). Tumor treatment in the oral cavity and pharynx commonly impairs swallowing capacity (I,V). In this project, only approximately one out of ten patients managed ordinary alimentation following treatment for oral and pharyngeal cancer. Permanent gastrostomias were needed by approximately one-third of the patients. Since surgical sequelae are instantaneous and obvious, other concurrent causes have been neglected. The prospective part of this project (II-V) constituted an inception follow-up, controlled when applicable (II-IV), and with tests and examinations performed before treatment, after radiotherapy, and six and 12 months after surgery. The study design allowed intra-individual comparisons, implying that any impact by e.g. smoking, dentures or age was already manifest prior to the onset of the study. This was essential because significant decrease in sensation has been reported at the tip of the tongue and in the hard palate in healthy smokers, in most intra-oral sites in denture wearers, and in all intra-oral sites in older patients (Cordeiro *et al.* 1997).

Statistically significant association was revealed between the degree of swallowing dysfunction on one hand and the degree of decline in intra-oral sensation and decreased ability to recognize different shapes on the other hand (V). The degree of decline in intra-oral sensation had a significant association with deterioration in intra-oral shape recognition and with hole size identification (V). Inferior bolus control is an effect that is expected to follow impaired capacity to sense material in the mouth after cancer treatment (V). This assumption is supported by a previous study reporting unilateral maxillary and mandibular anesthesia causing impaired mastication of bolus in healthy individuals (Kapur *et al.* 1990). It is reasonable to assume that the decline in ability to identify correct shape and size of test tools in the oral cavity (III, II) also implies problems judging the shape and size of a bolus. In consequence the patient is likely to swallow a bolus that is not properly masticated or not adequately adapted in size, both of which can cause fatal airway obstruction.

Many patients complain about difficulty maintaining sufficient alimentation during and after radiotherapy due to mucocitis, xerostomia, and inability to use dentures in a dry mouth. Impaired intra-oral sensation (IV) and muscle fibrosis (Laurell *et al.* 2003) contribute to the swallowing problems. Clinically observed dysphagia after radiotherapy was found to be linked with radiographic evidence of deterioration of swallowing function in approximately 20% of the patients. Radiotherapy has been reported to result in both immediate and long-term changes in swallowing function (Lazarus 1993b). Impairment in intra-oral sensation was shown to be delayed, not occurring immediately after radiotherapy but was manifest six months later (IV).

The degree of swallowing dysfunction was associated with the degree of impaired intra-oral sensation. Sensory impairment, induced by radiotherapy (IV), can be expected to also affect the pharynx, larynx, and upper esophageal sphincter, because the radiation field includes the lymph nodes of the neck due to the potential risk for metastases. The effect of impaired sensation of the oropharyngeal mucosa was tested in healthy individuals, who were given topical anesthesia to this region (Ertekin *et al.* 2000, Sulica *et al.* 2002). This resulted in an increased incidence of premature leakage, pharyngeal residual, laryngeal penetration, and aspiration, emphasizing the importance of intact sensory input for nor-

mal swallowing function. The frequency of the different experimentally induced signs of swallowing dysfunction was in accordance with the posttreatment findings of dysfunction observed in the patients after treatment for oral or pharyngeal cancer (V), this in spite of the patients' co-morbidities. Sensory decline in the oral cavity and the pharynx, caused by radiotherapy, with high probability explains why swallowing dysfunction, in patients treated for tumors in the oral cavity, is not restricted to the oral swallowing phase but includes the pharyngeal phase (V). Impaired intra-oral sensation in the back of the oral cavity can cause difficulty eliciting the swallowing reflex, resulting in premature leakage (Levring Jäghagen *et al.* 2003). This was observed in half of the patients following treatment. Furthermore, 15% of the patients were unable to initiate swallowing at all (V).

When healthy individuals were given unilateral mandibular short-term anesthesia, the intra-oral ability to discriminate shape and size remained unaltered (Mason 1967), most likely because the opposite side with its intact sensation compensated. This was reflected in the results of this project. Immediately after radiotherapy, intra-oral sensation was unaltered in the patients treated for oral or pharyngeal malignant tumor (IV) and the capability to identify shape and hole size remained unaltered. Six months after treatment, sensation declined as a late effect of the radiotherapy (IV). This sensory decline had a significant association with a decreased ability to identify shape and hole size (V).

The significant association between impaired sensation, hole size identification, shape recognition and swallowing dysfunction is reflected in this follow-up project (V). At the inceptive examination, immediately after diagnosis, nine out of ten patients could prepare and swallow a solid bolus, and eight of ten after the last radiotherapy session. Six months after surgery, however, only one-third of the patients were free of aspiration and able to masticate and swallow a solid bolus. Pharyngeal swallowing function deteriorated in more than 75% of the patients (V).

No recovery of intra-oral sensation, shape and size discrimination was observed between six and 12 months after treatment (II-IV), which was in line with previous findings (Aviv *et al.* 1992). Swallowing dysfunction remained impaired to the same degree or worsened in 88 % of the patients one-year after surgery compared to examination six months earlier (V). This is fully in agreement with a previous follow-up study comparing swallowing function one and 12 months after surgery for oral or pharyngeal cancer (Pauloski *et al.* 1994). Hence, there is little evidence of recovery with time.

The indication for providing a patient with a gastrostomia or a nasogastric feeding tube can vary. The patient might voluntarily refrain from swallowing due to fear of aspiration and socially embarrassing expectorations. The time needed for a meal could be so prolonged that, although able to swallow, the patient is provided with a gastrostomia for practical reasons. At the cineradiographic examination 12 months after surgery, four patients were incapable of performing a swallow (V). They were all provided with gastrostomias. It is noteworthy, that only four out of ten patients demonstrating aspiration were provided with a gastrostomia or a naso-gastric feeding tube (V). The explanation might be due to aspiration not consistently triggering the patients' cough. Decline of pharyngeal and laryngeal sensation could be responsible for inability to sense the presence of a bolus penetrating the laryngeal inlet. Silent aspiration is potentially life threatening because of the risk of repeated pneumonia. The present project has confirmed earlier results showing deterioration in sensation increases the risk of aspiration (Setzen *et al.* 2001, 2003).

The swallowing capacity after short-term topical anesthesia of the oral cavity, oropharynx, hypopharynx, and larynx in healthy volunteers, has controversially been reported to be normal or in need of only simple coaching (Bastian, Riggs 1999). Sensation is difficult to test in the oral cavity (IV), and sensation in the pharynx even worse, due to inaccessibility. A non-invasive model for assessing pharyngeal intra-luminal sensation has been reported (Aviv 2000), and should enable better comparison between studies and further exploration of pharyngeal swallowing.

Patients treated for oral tumors declined in their ability to identify hole size, six months after treatment, but patients treated for pharyngeal tumors did not (II). Shape recognition skills deteriorated significantly among patients treated for both oral and pharyngeal cancer (III). An explanation for the difference could be that scar formation in the oral cavity causing immobility of the tissues, has a larger impact on hole size identification, than sensation, that was shown to decline equally in the oral and pharyngeal groups. Surgery of pharyngeal cancer does not leave scars in the anterior part of the oral cavity where the test tools were examined by the patient.

Test design could explain the difference in results of shape and hole size discrimination tests (II,III). To choose a size from a test placard, showing circles of different diameters is easier than to describe or draw the shape of a test tool without being given alternatives of shapes. The most common error was to describe the shape as irregular (Fig. 6b). Shape recognition had a significant association with swallowing dysfunction but not hole size identification (V). One explanation could be that shape recognition is more important for adequate swallowing function than the ability to identify small sizes. Another explanation could be that hole size identification deteriorated significantly only among the patients with oral cancer and the sample of five patients with oral cancer who were statistically evaluated was small compared to the larger sample of 10 patients with pharyngeal cancer (V).

When shape recognition was tested (III), the healthy reference individuals demonstrated a learning effect, in that they performed better at the second test occasion compared to the first because they remembered the shapes of the test tools. This was expected, because healthy dental students, previously tested in shape recognition on two occasions with a four-year interval, performed better at the second test occasion, which was determined to be a learning effect (Landt 1983). In the present project, the patients did not demonstrate any learning effect at the second test occasion of shape recognition, after radiotherapy (III). At the time it was hypothesized that the absence of the learning effect was caused by deterioration due to radiotherapy (III). However, when intra-oral sensation was tested immediately after radiotherapy, there was no significant deterioration of sensation among the patients. Since sensation was unaltered there is no obvious explanation for the lack of learning effect among the patients. One possible reason could be the psychological effect due to the fact that the patients had recently been informed that they suffered from a severe and frightening disease, combined with pretreatment information, occupying their minds.

Since nerve tissue is known to be mitotically quiescent, it has not been considered radiosensitive. However, late radiotherapy injury to the blood supply might cause injury to the nerves of sensation, resulting in deterioration in sensation and decreased discriminatory skills after therapeutic 64 Gy radiotherapy, as demonstrated in this project (II-IV). Two phases of neuropathology following radiation have been suggested (Gillette *et al.* 1995). The early effect directly involves changes in electrophysiology and histochemistry. The late effect may be due to fibrosis in tissues surrounding the nerve, and/or injury to vessels supplying the nerves.

It has been shown that patients treated with only radiotherapy maintained function better than patients treated with a combination of radiotherapy and surgery (Bundgaard *et al.* 1993, Harrison *et al.* 1994, Allal *et al.* 2003). Oral cavity function following treatment for cancer has been examined and it was found that tongue mobility, speech and deglutition were better preserved after radiotherapy compared with diminished function following combined treatment. Patients treated solely with surgery had the best function, salivary flow, taste, and less postoperative pain (Teichgraeber *et al.* 1985). This highlights the dilemma of combined treatment, which is indicated with larger malignant tumors of the oral cavity and pharynx. Early detection, small tumors, and uncomplicated locations favor mono-treatment, while the combined treatment given patients participating in the present studies, are demonstrated to severely diminish oral function (I-V).

The use of microvascular free flaps in reconstruction following tumor surgery of the oral cavity or pharynx, is an improvement from the surgical point of view (I). For patients with malignant tumors, resection and reconstruction performed as a one-stage procedure is a great advantage. Reconstruction of the tissues does, however, not prevent swallowing disorders (I,V). In an evaluation of swallowing function, comparing three different free flaps for reconstruction in the head- and neck field, no significant differences between the radial free flap, the gastro-omental, and the jejunal free flap were found (Smith *et al.* 2002).

It has been suggested that primary closure maintains swallowing function better than reconstructive procedures with the introduction of tissue without sensation, with reduced mobility, and originating from other parts of the body (McConnel *et al.* 1998). A comparison of the degree of swallowing dysfunction between the patients reconstructed with a free flap and those with primary closure lent support to the opinion that swallowing function is maintained better after primary closure (V). Free flap reconstruction does not add tissue volume, but merely outlines the surgical defect (McConnel *et al.* 1994). Bolus residual can build up in the defect and spill over into the larynx and trachea, as was observed in the cineradiographic study (V).

To minimize complications from radiotherapy, different exercises for maintaining swallowing function have been recommended such as tongue-strengthening exercises to improve bolus manipulation and jaw movements to reduce the risk of trismus (Pauloski *et al.* 1998). At postoperative cineradiographic examinations, individualized strategies to optimize swallowing function can be identified, instructions can be given and performance of the instruction can be controlled. As an example, patients with residual in the pharynx after termination of the swallow can be helped to empty *e.g.* a surgical defect by guidance to a certain head posture during swallowing. Other patients with similar problems can be helped with the recommendation to drink water after swallowing a bolus in order to clear the pharynx of bolus residual. Different maneuvers for voluntary prolongation of airway closure or opening of the upper esophageal sphincter during swallowing can also be recommended for rehabilitation of swallowing function, in order to reduce the risk of aspiration (Lazarus *et al.* 1993a,b).

Future treatment modalities

At present, in Sweden, there is an ongoing, nation-wide, randomized, controlled study, Artscan (Accelerated radiotherapy of squamous cell carcinoma of the head and neck) (Fernberg 2004). The aim of the study is to evaluate the possibility of shortening the duration of radiotherapy to increase the effect on tumor cells, and hopefully on survival

rates, without increasing morbidity to normal tissue. Patients are randomized either to accelerated radiotherapy, giving two fractions a day during 4.5 weeks to 68 Gy, or to conventional radiotherapy, giving one fraction a day during 6.5-7 weeks, to 68 Gy.

It is an implicit assumption, that preserving the anatomy of an organ preserves the function of that organ. When brachy-radiotherapy is performed the radionuclides are placed in the tumor region via catheters. The treatment is fractionated (Leung 2002). The aim of the treatment is to reduce cosmetic morbidities, and to preserve the organs, and thereby, hopefully function without negatively affecting the cure. The long term impact on intra-oral sensation using this treatment has not yet been explored. Whether internal radiation diminishes intra-oral sensation and ability to discriminate, and causes swallowing dysfunction is not known and remains to be explored.

The combination of cytotoxic drugs and external beam radiotherapy, tends to preserve the functional integrity of the organs, and is used increasingly today. Bilateral radiotherapy combined with chemotherapy was demonstrated in a videoradiographic evaluation to cause swallowing disorders (Lazarus *et al.* 1996). In another study of patients treated similarly for oropharyngeal cancer, swallowing ability also deteriorated. The complications were related to mucositis during the treatment period, and dysphagia due to fibrosis and included aspiration pneumonia (Machtay *et al.* 2002). The complications are similar to those seen with radical surgical approaches, raising the question of what treatment modality provides the best quality of life.

The future will reveal if tissue matching combined with immunosuppressive drugs will allow, for instance, transplantation of the tongue, as has already been described in an animal model (Brown 2001).

In evaluation of different treatment modalities, survival is the guiding principle. As the number of surviving patients increases, it is a necessity to explore the entire range of sequelae of the different therapies, in order to recommend the one that causes the least morbidity to patients. Since patients have to live their entire posttreatment life with the treatment sequelae, realistic pretreatment information is essential to the patients. Not until the whole spectrum of morbidities following different treatments is known, can effective rehabilitation strategies be developed. The present project, demonstrating the significant deterioration of sensation following radiotherapy and surgery (IV), and its association with decline in intra-oral ability to discriminate (II,III) as well as swallowing disorders (V), serves that purpose.

CONCLUSIONS

- Delayed intra-oral sensory decline, found to be induced by radiotherapy, can be expected to appear in the entire radiation field, including the oral cavity and the pharynx, with adverse effect on swallowing.
- Testing intra-oral sensation close to the last radiotherapy session is not advisable, because sensory decline does not develop immediately after radiotherapy but manifests after six months.
- Spontaneous sensory rehabilitation cannot be expected after six months.
- The significant association between degree of swallowing dysfunction and degree of intra-oral sensory decline and impaired discrimination ability must be considered in the quest for functional rehabilitation of patients treated for oral or pharyngeal cancer.

In 1953 Erik Moberg stated that: "without sensation, the hand is blind (Dellon1990)."
I would add: "Without sensation the mouth is blind."

REFERENCES:

Allal AS, Nicoucar K, Mach N, Dulguerov P. Quality of life in patients with oropharynx carcinomas: assessment after accelerated radiotherapy with or without chemotherapy versus radical surgery and postoperative radiotherapy. *Head Neck* 2003; 25:833-840.

Aviv JE, Hecht C, Weinberg H, Dalton JF, Urken ML. Surface sensibility of the floor of the mouth and tongue in healthy controls and in irradiated patients. *Otolaryngol Head Neck Surg* 1992; 107:418-423.

Aviv JE. Clinical Assessment of Pharyngolaryngeal Sensitivity. *Am J Med* 2000; 108:68S-72S.

Barón AE, Franceschi S, Barra S et al. A comparison of the joint effects of alcohol and smoking on the risk of cancer across sites in the upper aero-digestive tract. *Cancer Epidemiology, Biomarkers and Prevention* 1993; 2:519-523.

Bastian RW, Riggs LC. Role of sensation in swallowing function. *Laryngoscope* 1999; 109:1974-1977.

Baum BJ, Bodner L, Fox PC et al. Therapy-induced dysfunction of salivary glands: implications for oral health. *Spec Care Dent* 1985; 5: 274-277.

Bentzen SM, Thames HD, Overgaard M. Latent-time estimation for late cutaneous and subcutaneous radiation reactions in a single-follow-up clinical study. *Radiother Oncol* 1989; 15:267-274.

Berkovitz BK, Holland GR, Moxham BJ. A Colour Atlas and text of Oral anatomy. Histology and Embryology. Third ed Wolfe publ Ltd 2002. Aylesbury, Bucks: pp 78-82, 95-98.

Beumer J, Silverman S, Benak SB. Hard and soft tissue necrosis following radiation therapy for oral cancer. *J Prosthet Dent* 1972; 27:640-644.

Bjoridal K, Kaasa S, Mastekaasa A. Quality of life in patients treated for head and neck cancer: A follow-up study 7 to 11 years after radiotherapy. *Int J Radiat Oncol Biol Phys* 1994; 28:847-856.

Brown AE. Functional reconstruction of the tongue: Can we do better? *Br J Oral Maxillofac Surg* 2001; 39:256-259.

Bundgaard T, Tandrup O, Elbrönd O. A functional evaluation of patients treated for oral cancer. A prospective study. *Int J Oral Maxillofac Surg* 1993; 22:28-34.

Cordeiro PG, Schwartz M, Neves RI, Tuma R. A comparison of donor and recipient site sensation in free tissue reconstruction of the oral cavity. *Ann Plast Surg* 1997; 39:461-468.

- Coutard H. Principles of X-ray therapy of malignant diseases. *Lancet* 1934; 7:1-8.
- Croche A, Moretti A, D'Agostino L, Neri G. Continuing validity of pectoralis major muscle flap 25 years after its first application. *Acta Otorhinolaryngol Ital.* 2003; 4:297-304.
- Curtis DJ, Cruess DF, Dachmann AH, Maso E. Timing in the normal pharyngeal swallow. *Invest Radiol* 1984; 19:523-529.
- Davis JW, Lazarus C, Logemann J et al. Effect of a maxillary glossectomy prosthesis on articulation and swallowing. *Prosthet Dent* 1987; 57:715-719.
- Day TA, Davis BK, Boyd Gillespie M et al. Oral cancer treatment. *Current Treatments Options in Oncology* 2003; 4:27-41.
- De Boer MF, McCormick LK, Pruyn JFA et al. Physical and psychosocial correlates of head and neck cancer: A revue of the literature. *Otolaryngol Head Neck Surg* 1999; 120: 427-436.
- Dellon AL. The sensational contributions of Erik Moberg. *J Hand Surg Br* 1990; 15B:14-24.
- DeNittis AS, Machtay M, Rosenthal DI et al. Advanced Oropharyngeal Carcinoma Treated with Surgery and Radiotherapy. Oncologic outcome and Functional Assessment. *Am J Otolaryngol* 2001; 22:329-335.
- El-Mofty SK, Kahn AJ. Early membrane injury in lethally irradiated salivary gland cells. *Int J Radiat Biol* 1981; 39:55-62.
- Emami B, Lyman J, Brown A et al. Tolerance of normal tissue to therapeutic irradiation. *Int J Radiat Oncol Biol Phys* 1991; 21:109-122.
- Ertekin C, Kiylioglu N, Tarlaci S et al. Effect of mucosal anaesthesia on oropharyngeal swallowing. *Neurogastroenterol Mot.* 2000; 12:567-572.
- Fernberg Artscan Personal communication 2004.
- Franzen L, Funegård U, Eriksson Th et al. Parotid Gland Function During and Following Radiotherapy of Malignancies in the Head and Neck. A consecutive study of salivary flow and patient discomfort. *Eur J Cancer* 1992; 28:457-462.
- Gaziano JE. Evaluation and management of oropharyngeal dysphagia in head and neck cancer *Cancer Control* 2002; 9:400-409.
- Giese WL, Kinsella TJ. Radiation injury to peripheral and cranial nerves. In Gutin PH, Leibel SA and Sheline GE eds. *Radiation Injury to the Nervous System*. New York, NY: Raven Press, Ltd.; 1991:383-403.

Gillette EL, Mahler PA, Powers BE et al. Late radiation injury to muscle and peripheral nerves. *Int J Radiat Oncol Biol Phys* 1995; 31:1309-1318.

Goldstein M, Maxymiv WG, Cummings BJ et al. The effects of antitumor irradiation on mandibular opening and mobility: A prospective study of 58 patients. *Oral Surg Oral Med Oral Pathol Oral Radiol Endod* 1999; 88:365-373.

Hagopian G: Oncolink Internet: [http:// www.oncolink.upenn.edu/](http://www.oncolink.upenn.edu/) The Trustees of the University of Pennsylvania 1996.

Harrison LB, Zelewski MJ, Armstrong JG et al. Performance status after treatment for squamous cell cancer of the base of tongue- a comparison of primary radiation therapy versus primary surgery. *Int J Radiat Oncol Biol Phys* 1994; 30:953-957.

Henkin RI, Banks V. Tactile perception on the tongue, palate and the hand of normal man. In: Bosma J F, editor. *Symposium on oral sensation and perception*. Springfield: Thomas; 1967:182-187.

Kaasa S, Wist E, Höst H. *Palliativ strålbehandling Studentlitteratur*, Lund 1996. pp148-151.

Kapur KK, Garrett NR, Fisher E. Effects of anesthesia of human oral structures on masticatory performance and food particle size distribution. *Archs oral Biol* 1990; 35:397-403.

Kinsella TJ, Weichselbaum RR, Sheline GE. Radiation injury of cranial and peripheral nerves In Gilbert HA, Kagan AR eds. *Radiation damage to the nervous system*. New York: Raven Press 1980:145-153.

Landt H. Oral stereognosis and oral muscular coordination ability. *Front Oral Physiol* 1983; 4:55-79.

Langmore SE. Managing the complications of aspiration in dysphagic adults In: *Seminars in Speech and Language Swallowing disorders* Barbara Sonies Ed. Richard F Curlee New York 1991; 12:199-207.

Laurell G, Kraepelien T, Mavroidis P et al. Stricture of the proximal esophagus in head and neck carcinoma patients after radiotherapy. *Cancer* 2003; 97:1693-1700.

Lazarus C, Logemann JA, Gibbons P. Effects of maneuvers on swallowing function in a dysphagic oral cancer patient. *Head Neck* 1993a; 15:419-424.

Lazarus CL. Effects of radiation therapy and voluntary maneuvers on swallow functioning in head and neck cancer patients. *Clin Comm Disord* 1993b; 3:11-20.

Lazarus CL, Logemann JA, Pauloski BR et al. Swallowing disorders in head and neck cancer patients treated with radiotherapy and adjuvant chemotherapy. *Laryngoscope* 1996; 106:1157-1166.

Lazarus CL. Management of swallowing disorders in head and neck cancer patients: Optimal patterns of care. *Seminars of speech and language* 2000; 4:293-309.

Lear CSC, Flanagan JB, Moorrees CFA. The frequency of deglutition in man. *Arch oral Biol* 1965; 10:83-99.

Leibel SA, Sheline GE. Tolerance of the central and peripheral nervous system to therapeutic irradiation. *Adv Radiol Biol* 1987; 12:257-288.

Leung TW, Wong VY, Kwan KH et al. High dose rate brachytherapy for early stage oral tongue cancer. *Head Neck* 2002; 24:274-281.

Levring Jäghagen E, Franklin KA, Isberg A. Snoring, sleep apnoea and swallowing dysfunction: A videoradiographic study. *Dentomaxillofac Radiol* 2003; 32:311-6.

Linden-Castelli P. Treatment strategies for adult neurogenic dysphagia. In: *Seminars in Speech and Language, Swallowing disorders* Barbara Sonies Ed. Richard F Curlee New York 1991; 12:255-261.

Logemann JA. Rehabilitation of Oropharyngeal Swallowing disorders. *Acta oto-rhino-laryngologica belg* 1994; 48:207-215.

Logemann, JA, Pauloski BR, Rademaker AW et al. Super-supraglottic swallow in irradiated head-and neck cancer patients. *Head and Neck* 1997a; 19:535-540.

Logemann JA, Pauloski BR, Rademaker AW et al. Speech and swallowing rehabilitation for head and neck cancer patients. *Oncology* 1997b; 11:651-664.

Machtay M, Rosenthal DI, Heshock D et al. Organ preservation therapy using induction plus concurrent chemoradiation for advanced respectable oropharyngeal carcinoma: a University of Pennsylvania Phase II trial. *J Clin Oncol* 2002; 20:3964-3971.

McConnel FM, Logemann JA, Rademaker AW, et al. Surgical Variables affecting postoperative swallowing efficiency in oral cancer patients: A pilot study. *Laryngoscope* 1994; 104:87-90.

McConnel FM, Pauloski BR, Logemann JA, et al. Functional results of primary closure vs flaps in oropharyngeal reconstruction: A prospective study of speech and swallowing. *Arch Otolaryngol Head Neck Surg* 1998; 124:625-630.

Mason RM. Studies on oral perception involving subjects with alterations in anatomy and physiology. In Bosma JF, editor, *Symposium on oral sensation and perception* Springfield (IL): Charles C Thomas Publisher; 1967:294-301.

Miller AJ. Deglutition. *Physiol Rev* 1982; 62:129-184.

Palmer JB, Drennan JC, Baba M. Evaluation and treatment of swallowing impairments: *Am Fam Physician* 2000; 61:2453-2462.

Pauloski BR, Logemann JA, Rademaker AW, et al. Speech and swallowing function after oral and oropharyngeal resections: one year follow-up. *Head Neck* 1994; 16:313-322.

Pauloski BR, Rademaker AN, Logemann JA, Colangelo LA. Speech and swallowing in irradiated and nonirradiated postsurgical oral cancer patients. *Otolaryngol Head Neck Surg* 1998;118:616-24.

Pauloski BR, Rademaker AW, Logemann JA et al. Swallow function and perception of dysphagia in patients with head and neck cancer. *Head Neck* 2002; 24: 555-565.

Perlman AL. The neurology of swallowing. In: Sonies BC, Swallowing disorders, *Seminars in speech and language* Ed. Richard F Curlee New York 1991; 12:171-183.

Petrén T, Carlsöö S. Anatomii för tandläkarstuderande och tandläkare 5:e omarbetade upplagan Gummessons Boktryckeri AB, Falköping 1983: 173-198.

Piso DU, Eckardt A, Liebermann A et al. Early rehabilitation of head-neck edema after curative surgery for orofacial tumors. *Am J Phys Med Rehabil* 2001;80:261-269.

Pruyn JFA, de Jong PC, Bosman LJ et al. Psychosocial aspects of head and neck cancer-a review of the literature. *Clin Otolaryngol* 1986; 11: 469-474.

Ries LAG, Eisner MP, Kosary CL et al. SEER Cancer statistics revue 1973-1999. Bethesda: National Cancer Institute; 2002.

Rogers SN, Lowe D, Fisher SE et al. Health-related quality of life and clinical function after primary surgery for oral cancer. *Br J Oral Maxillofac Surg* 2002; 40:11-18.

Rubin RL, Doku HC. Therapeutic radiology- the modalities and their effects on oral tissues *JADA* 1976; 92:731-739.

Salassa JR. A functional outcome, swallowing scale for staging oropharyngeal dysphagia. *Dig Dis* 1999; 17:230-234.

Schliephake H, Jamil MU. Prospective evaluation of quality of life after oncologic surgery for oral cancer *Int J Oral Maxillofac Surg* 2002; 31:427-433.

Setzen M, Cohen MA, Mattucci KF et al. Laryngopharyngeal sensory deficits as a predictor of aspiration. *Otolaryngol Head Neck Surg.* 2001; 124:622-624.

Setzen M, Cohen MA, Perlman PW et al. The association between laryngopharyngeal sensory deficits, pharyngeal motor function, and the prevalence of aspiration with thin liquids. *Otolaryngol Head Neck Surg.* 2003; 128:99-102.

Smith GI, Brennan PA, Scott PJ et al. Outcome after radial forearm, gastro-omental, and jejunal free flaps in oral and oropharyngeal reconstruction. *Br J Oral Maxillofac Surg.* 2002; 40:330-333.

Sobotta Atlas of Human anatomy. Volume 1. Head, Neck, Upper limb, 12th English Edition, Urban and Schwarzenberg. Munich, Vienna, Baltimore. 1994:91-114, 116-117, 132-159.

Sulica L, Hembree A, Blitzer A Swallowing and sensation: evaluation of deglutition in the anesthetized larynx. *Ann Otol Rhinol Laryngol.* 2002; 111:291-294.

Takimoto T, Saito Y, Suzuki M et al. Radiation-induced cranial nerve palsy: hypoglossal nerve and vocal cord palsies. *J Laryngol Otol* 1991; 105:44-45.

Talmi YP. Minimizing complications in neck dissection. *J Laryngol Otol* 1999; 113:101-113.

Talmi YP. Quality of life issues in cancer of the oral cavity. Review article. *J Laryngol Otol* 2002; 116:785-790.

Teichgraeber J, Bowman J, Goepfert H. New test series for the functional evaluation of oral cavity cancer. *Head Neck Surg* 1985; 8:9-20.

Thames HD, Bentzen SM, Turesson I et al. Time- dose factors in radiotherapy: a review of the human data. *Radiother Oncol* 1990; 19: 219-235.

Tibbling Grahn L. Dysphagia. A common but hidden handicap (In Swedish). *Läkartidningen* 1996; 93:4249-4251.

Östman J, Anneroth G, Gustavsson H et al. Malignant oral tumors in Sweden 1960-1989- an epidemiological study. *Oral Oncol, Eur J Cancer* 1995; 31B :106-112.